

“Oral manifestation and oral health status in Covid-19: An observational human study”

Dr. Maya S. Indurkar¹, Dr. Manjiri B. Saoji²

¹Government Dental College And Hospital, Aurangabad. Department of Periodontology

²Government Dental College And Hospital, Aurangabad, Maharashtra, India

ABSTRACT

Background: Severe acute respiratory syndrome coronavirus 2 (SARS-CoV-2) is a single chain, plus stranded RNA virus belonging to the family of Coronaviridae, responsible for causing covid-19 disease. In literature, abundant studies have reported about the clinical signs observed in SARS-CoV-2 patients but majority of them have not verified the oral health status. Therefore, the aim of the present study is to evaluate the oral manifestation in covid positive patients and to obtain more information about their oral health status.

Methods: 200 participants were enrolled in this observational study with the aim to obtain more information about the oral health status and associated oral manifestation in patients positive for SARS-CoV-2 by using an online questionnaire consisting of demographic details and fifteen close ended questions.

Results: Amongst 200 participants 20% reported of irregular brushing of teeth, 94.5% reported of irregular use of interdental aid and 77% reported of infrequent use of tongue cleaner during the period of active covid infection. Most common oral manifestation observed were alteration/loss of smell (40.5%), alteration/loss of taste (46%), difficulty in swallowing (47.5%) and xerostomia (21.5%) whereas the least common oral manifestation noted were rash on face (2%) and swelling inside the oral cavity (5%).

Conclusions: This study illustrates a close relationship between SARS-CoV-2 and its associated oral manifestation. Early diagnosis of the oral lesion along with proper treatment might help to reduce the disease transmission and associated oral complications

Keywords: SARS-CoV-2, oral manifestation, covid-19, oral health status.

INTRODUCTION

Severe acute respiratory syndrome coronavirus 2 (SARS-CoV-2) is a single chain, plus stranded RNA virus belonging to the family of Coronaviridae, responsible for causing covid-19 disease.^[1,2] The initial phase in the SARS-CoV-2 infection is the virus entry into the host cell. The major route for virus transmissions is direct through coughing, sneezing, salivary droplet expelled during the phonation, or indirect by contact with the body mucous membranes such as oral, nasal and ocular.^[3-6] After entering the host, the virus spike protein interacts with the angiotensin-converting enzyme 2 (ACE2) receptors. Any organ with ACE2 expressing cells is plausibly vulnerable to SARS-CoV-2 infection.^[7] The main symptoms of Covid-19 are fever, tiredness, and dry cough. Some patients may experience muscle pain, sore throat, nasal congestion, runny nose, or diarrhoea, but in severe cases, the infection can cause pneumonia, severe acute respiratory syndrome, kidney failure, and even death.^[3] In literature, abundant studies have reported about the clinical signs observed in SARS-CoV-2 patients but majority of them have not verified the oral health status.^[8] Few studies and case reports on oral manifestations related to SARS-CoV-2 have been described in literature.^[9-11] Possible oral manifestation include: hypogeusia/ageusia, xerostomia, chemosensory alterations, non-specific anosmia and hyposalivation.^[12-14] Few reports also state about unexplained ulcers in the oral cavity, desquamative gingivitis, herpetiform ulcers on attached gingiva, blisters/irregular ulcers on the dorsal surface of tongue, enlargement of cervical lymph node, enlargement of submandibular glands, erythematous rash on the face or viral enanthema in SARS-CoV-2 positive patient.^[9,10] Therefore, the aim of the present study is to evaluate the oral manifestation associated with Covid-19 and to obtain more information about the oral health status of patient positive for Covid-19.

MATERIALS AND METHODS

This study was conducted by department of periodontology, Government dental college and hospital, Aurangabad between March-April 2021 through an online questionnaire in patients testing positive for SARS-CoV-2. A total of 200

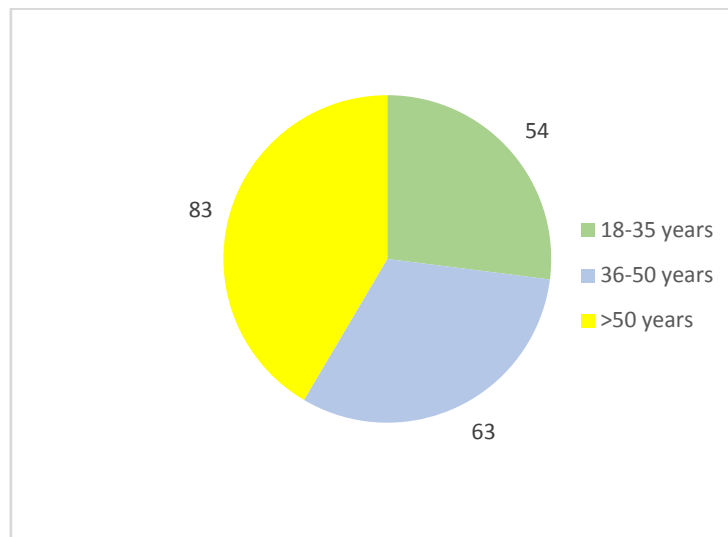
patients were enrolled in this observational study. A questionnaire consisting demographic detail and 15 closed ended questions was given to the participants with the aim to collect more information regarding the oral health status and oral manifestation in Covid-19 patients. The questionnaire was provided in 3 language (Hindi/Marathi/English) so that the participants are able to understand the questions with ease. The study was conducted in accordance with the Helsinki Declaration of 1975, as revised in 2000

RESULTS

Overall, 200 Covid positive patients were enrolled in the study whose demographic details are presented in graph 1 and graph 2. [Graph 1](#) displays the age of the participants enrolled in the study. It was observed that lesser number of participants were from age group 18 -35 years whereas maximum participants were from age group >50 years. [Graph 2](#) displays the gender of the participants. It was noted that out of 200 participants 115 were men and 85 were women.

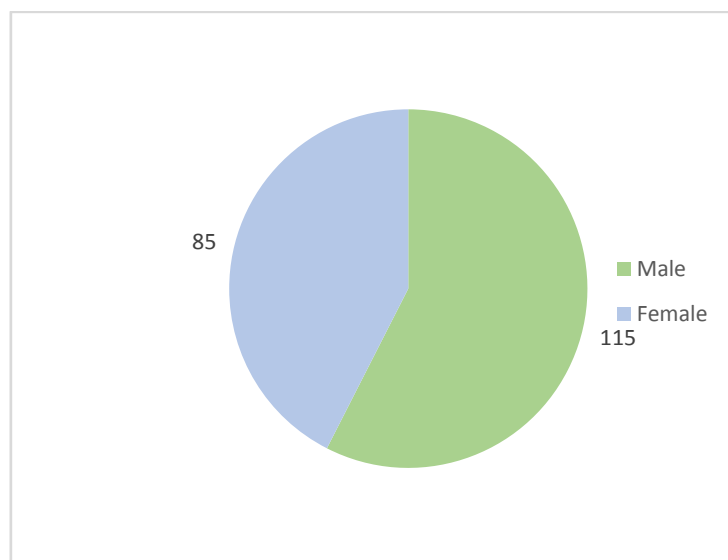
The result from [graph 3](#) demonstrates that amongst 200 participants 20% reported of irregular brushing of teeth, 94.5% reported of irregular use of interdental aid and 77% reported of infrequent use of tongue cleaner during the period of active Covid-19 infection. Most common oral manifestation observed were alteration/loss of smell (40.5%), alteration/loss of taste (46%), difficulty in swallowing (47.5%) and xerostomia (21.5%) whereas the least common oral manifestation noted were rash on face (2%) and swelling inside the oral cavity or on face (5%).

Graph 1.



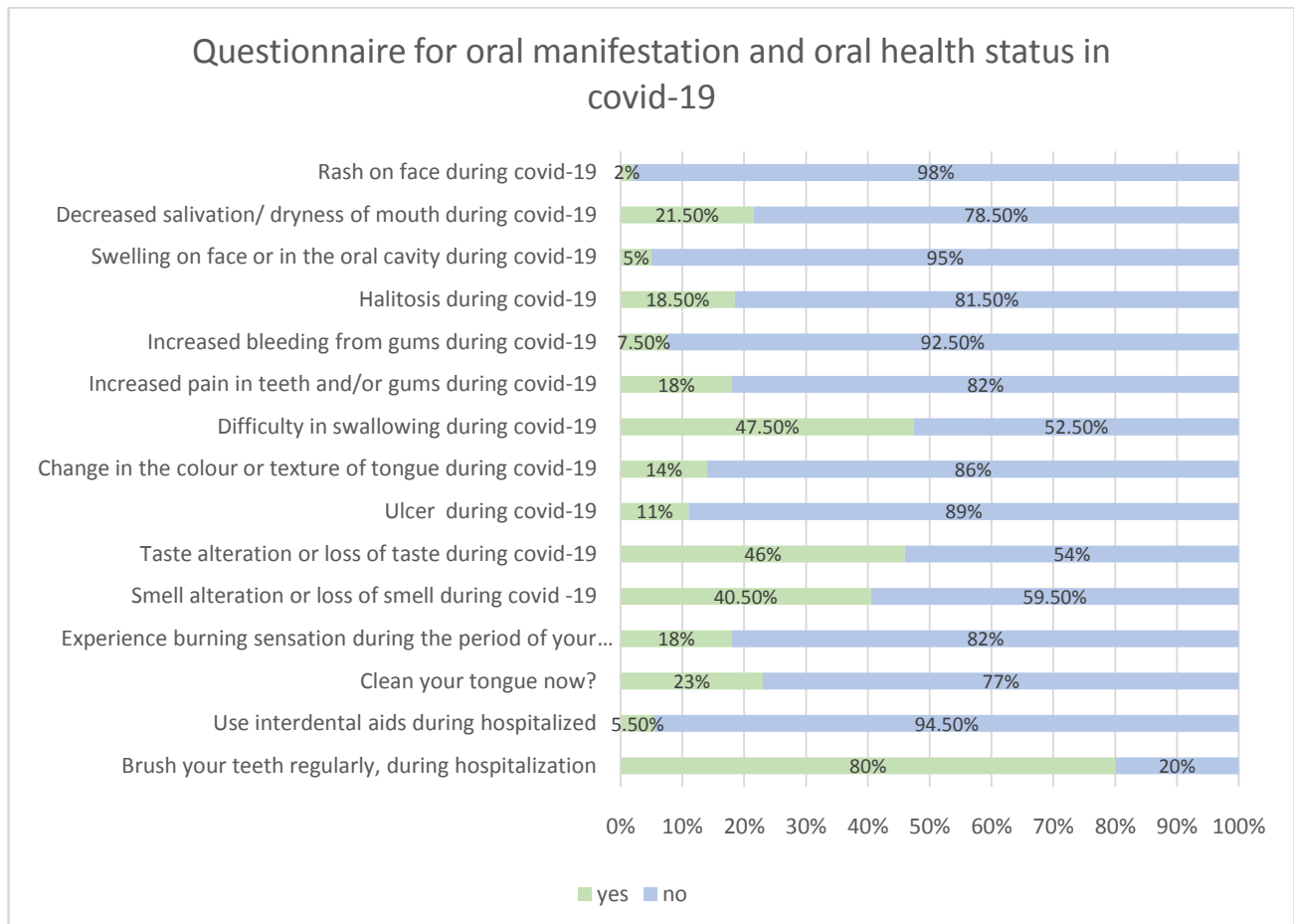
Graph 1: Age of the participants enrolled for the study.

Graph 2



Graph 2: Gender of the participants enrolled for the study.

Graph 3



Graph 3: Questionnaire for oral manifestation and oral health status in covid-19

DISCUSSION

The role of oral mucosa as a possible route of SARS-CoV-2 transmission has been previously reported in many studies.^[15] In addition, several studies and case reports have described the common oral manifestation seen in Covid-19 patients but there is a scarcity of data on oral hygiene status of covid-19 patients.^[9-11] Therefore, this study was performed to identify various oral manifestation present in patient positive for SARS-CoV-2 and to obtain more information about their oral health status.

It was observed that patient's attention towards oral health declined after developing covid -19 symptoms like fever, cough, weakness and muscle pain. Oral hygiene practices like regular brushing of teeth, use of interdental aid and tongue cleaner diminished to a greater extent as the focus shifted more towards systemic health.

Loss of taste sensation was seen in 46% participants. Ageusia can be attributed to the presence of higher numbers of ACE2 expressing cells in the epithelium of oral tissues and nasal mucosa.^[16,17] The spike protein of SARS-CoV-2 have affinity ACE2 expressing cells, leading to certain chemosensory changes causing ageusia. The ACE2 expressing cells are more profound in gustatory receptors of the tongue than the buccal or gingival tissues.^[7] 40.5% participants complained of coronavirus-induced anosmia or hyposmia. Anosmia/hyposmia may be due to the direct effect of the virus on the function of sustentacular cells, by downscaling the odorant clearing function, or by invoking secondary metabolic dysfunction of the olfactory receptor neurons.^[18] Different studies indicate that the SARS-CoV-2 virus is present in the whole saliva in the primary stages of Covid-19 and is even detectable in the saliva secreted from salivary gland ducts after several days.^[19] Virus penetration into salivary glands affects the function of these glands in the initial stages of the disease causing changes in salivary flow and components.^[19,20] The neuropathic and mucotropic effects of this virus can potentially affect the function of salivary glands and can lead to hyposalivation and xerostomia.^[21] In addition, use of mask may causes mouth breathing which can desiccate oral tissue especially without frequent hydration. Consuming numerous medicines of diverse pharmacological groups is amongst other reasons suggested for xerostomia in Covid-19. In this study 21.5% participants complained of hyposalivation or xerostomia. Hyposalivation deteriorates the oral hygiene by reducing the clearing capacity of saliva and furthermore causing accumulation of food

debris leading to halitosis, dental caries and periodontal diseases. 11% participants presented with oral ulcer. The presence of oral ulcer in covid-19 was previously reported by many authors but its etiology remained uncertain.^[10,22] The presentation of oral ulcer may be due to the infection itself or because of anxiety and stress due to the restrictions of social life during confinement causing development of aphthoid ulcers or herpetic recurrences. Tissue necrosis including oral ulcerations can also occur due to vessel damage. Ulceration and tissue damage can further intensify by increased inflammation and upregulation in inflammatory markers due to the SARS-CoV-2 virus.^[23] Several authors reported a coexistence between the presence or the suspicion of covid-19 and oral ulcers. It is therefore important to carry out a SARS-CoV-2 RT-PCR in patient presenting oral ulcers of unknown origin. Increase tooth ache in Covid-19 patient may be attributed to infrequent use of oral hygiene aids, dental caries, mobility and bruxism. 18% participants presented with increased pain in teeth and gums whereas 7.5 % complained of increased bleeding from gums. Poor oral hygiene causes accumulation of debris and plaque leading to irritation of gum and thus increased bleeding. Several studies have mentioned about association between gum disease and Covid-19 severity. Takahashi et.al suggested that aspiration of periodontopathic bacteria which are associated with gum disease might aggravate Covid-19 by inducing the expression of angiotensin- converting enzyme 2, and inflammatory cytokines in the lower respiratory tract.^[24] Also, it was suggested that periodontopathic bacteria might enhance SARS- CoV- 2 virulence by cleaving its S glycoproteins and that the oral cavity, and specially periodontal pockets could act as a viral reservoir.^[24-30] Sahni et.al suggested that the strong Th17 response in severe periodontitis could exacerbate the cytokine storm in COVID- 19.^[31]

Early diagnosis of oral manifestation beside RT PCR and blood investigation can remarkably reduce the disease transmission. Although this observational study reports some striking data on oral manifestation and oral health status of SARS-CoV-2 positive patients, it had various limitation such as small sample size and the difficulty in enrolling participants as it was an online questionnaire study. We recommend regular brushing of teeth, use of interdental aid, tongue cleaner and mouthwash in Covid-19 positive patient to reduce further consequence's associated with poor oral hygiene like periodontal disease and fungal infection.

CONCLUSION

This study illustrates a close relationship between SARS-CoV-2 and its associated oral manifestation. The most prevalent oral manifestation observed were anosmia, ageusia and hyposalivation. The availability of data on the aetiopathogenesis of oral lesion is limited and uncertain. Timely identification and proper treatment of oral manifestation might help to reduce the further complications. More studies need to be conducted on a larger scale to better understand the relationship between SARS-CoV-2 and its oral manifestation.

REFERENCES

- [1]. Wu F et al. A new coronavirus associated with human respiratory disease in China. *Nature*. 2020;579:265-9.
- [2]. Wang Y, Grunewald M, Perlman S. Coronaviruses: an updated overview of their replication and pathogenesis. *Methods Mol Biol*. 2020;2203:1-29.
- [3]. Zhang X, Zhang L. Epidemiological and clinical characteristics of 99 cases of 2019 novel coronavirus pneumonia in Wuhan, China: a descriptive study. *Lancet*. 2020;395:507-513.
- [4]. Epidemiology Working Group for NCIP Epidemic Response, Chinese Center for Disease Control and Prevention. [The epidemiological characteristics of an outbreak of 2019 novel coronavirus diseases (COVID-19) in China]. *Zhonghua Liu Xing Bing Xue Za Zhi*. 2020;41:145-151.
- [5]. To KK et al. Consistent detection of 2019 novel coronavirus in saliva. *Clin Infect Dis*. 2020;41(2):841-43.
- [6]. Infection control recommendations for the dental office and the dental laboratory. ADA Council on Scientific Affairs and ADA Council on Dental Practice. *J Am Dent Assoc*. 1996;127:672-80.
- [7]. Xu H et al. High expression of ACE2 receptor of 2019-nCoV on the epithelial cells of oral mucosa. *Int J Oral Sci*. 2020;12:8.
- [8]. Wang D et al. Clinical course and outcome of 107 patients infected with the novel coronavirus, SARS-CoV-2, discharged from two hospitals in Wuhan, China. *Crit Care*. 2020;24:188.
- [9]. Martín Carreras-Presas C, Amaro Sánchez J, López-Sánchez AF, Jané-Salas E, Somacarrera Pérez ML. Oral vesiculobullous lesions associated with SARS-CoV-2 infection. *Oral Dis*. 2021;27:710-12.
- [10]. Chaux-Bodard AG, Deneuve S, Desoutter A. Oral manifestation of Covid-19 as an inaugural symptom. *Journal of Oral Medicine and Oral Surgery*. 2020;26:18.
- [11]. Soares CD, Carvalho RA, Carvalho KA, Carvalho MG, Almeida OP. Letter to Editor: Oral lesions in a patient with Covid-19. *Med Oral Patol Oral Cir Bucal*. 2020;25:563-64.
- [12]. Vinayachandran D, Balasubramanian S. Is gustatory impairment the first report of an oral manifestation in COVID-19. *Oral Dis*. 2021;27:748-49.
- [13]. Lee Y, Min P, Lee S, Kim SW. Prevalence and Duration of Acute Loss of Smell or Taste in COVID-19 Patients. *J Korean Med Sci*. 2020;35:174.
- [14]. Vaira LA et al. Objective evaluation of anosmia and ageusia in COVID-19 patients: Single-center experience on 72 cases. *Head Neck*. 2020;42:1252-58.

- [15]. Xu J, Li Y, Gan F, Du Y, Yao Y. Salivary Glands: Potential Reservoirs for COVID-19 Asymptomatic Infection. *J Dent Res.* 2020;99:989.
- [16]. Zou X, Chen K, Zou J, Han P, Hao J, Han Z. Single-cell RNA-seq data analysis on the receptor ACE2 expression reveals the potential risk of different human organs vulnerable to 2019-nCoV infection. *Front Med.* 2020;14:185-192.
- [17]. Ren X et al. Analysis of ACE2 in polarized epithelial cells: surface expression and function as receptor for severe acute respiratory syndrome-associated coronavirus. *J Gen Virol.* 2006 Jun;87(Pt 6):1691-1695.
- [18]. Butowt R, von Bartheld CS. Anosmia in COVID-19: Underlying Mechanisms and Assessment of an Olfactory Route to Brain Infection. *Neuroscientist.* 2021:1073858420956905.
- [19]. Bagley AF et al. Xerostomia-related quality of life for patients with oropharyngeal carcinoma treated with proton therapy. *Radiotherapy and Oncology.* 2020;142:133-9.
- [20]. da Silva Pedrosa M, Sipert CR, Nogueira FN. Altered taste in patients with COVID-19: The potential role of salivary glands. *Oral Dis.* 2021;27:798-800.
- [21]. Dziedzic A, Wojtyczka R. The impact of coronavirus infectious disease 19 (COVID-19) on oral health. *Oral Dis.* 2021;27:703-6.
- [22]. Abu-Hammad S, Dar-Odeh N, Abu-Hammad O. SARS-CoV-2 and oral ulcers: A causative agent or a predisposing factor? *Oral Dis.* 2020 Jun 21:10.1111/odi.13498..
- [23]. Sampson V, Kamona N, Sampson A. Could there be a link between oral hygiene and the severity of SARS-CoV-2 infections? *Br Dent J.* 2020;228:971-75.
- [24]. Takahashi Y, Watanabe N, Kamio N, Kobayashi R, Iinuma T, Imai K. Aspiration of periodontopathic bacteria due to poor oral hygiene potentially contributes to the aggravation of COVID-19. *J Oral Sci.* 2020;63:1-3.
- [25]. Madapusi Balaji T et al. Oral cancer and periodontal disease increase the risk of COVID 19? A mechanism mediated through furin and cathepsin overexpression. *Med Hypotheses.* 2020;144:109936.
- [26]. Badran Z, Gaudin A, Struillou X, Amador G, Soueidan A. Periodontal pockets: A potential reservoir for SARS-CoV-2? *Med Hypotheses.* 2020;143:109907.
- [27]. Bao L, Zhang C, Dong J, Zhao L, Li Y, Sun J. Oral Microbiome and SARS-CoV-2: Beware of Lung Co-infection. *Front Microbiol.* 2020;11:1840.
- [28]. Botros N, Iyer P, Ojcius DM. Is there an association between oral health and severity of COVID-19 complications? *Biomed J.* 2020;43:325-7.
- [29]. Herrera D, Serrano J, Roldán S, Sanz M. Is the oral cavity relevant in SARS-CoV-2 pandemic? *Clin Oral Investig.* 2020;24:2925-30.
- [30]. Kheur S, Kheur M, Gupta AA, Raj AT. Is the gingival sulcus a potential niche for SARS-Corona virus-2? *Med Hypotheses.* 2020;143:109892.
- [31]. Sahni V, Gupta S. COVID-19 & Periodontitis: The cytokine connection. *Med Hypotheses.* 2020;144:109908.