

# Natal Teeth: Revisited

Dr. Jogender Kumar Jangra<sup>1</sup>, Dr. Ravinder Solanki<sup>2</sup>, Dr. Monika Khokhar<sup>3</sup>

<sup>1</sup>MDS (Oral & Maxillofacial Surgery), Consultant Oral Surgeon at Shri Ganesh Dental Clinic and Maxillofacial Centre  
Rohtak Haryana

<sup>2</sup>MDS (Oral & Maxillofacial Surgery), Associate Professor, PGIDS, Rohtak Haryana

<sup>3</sup>Consultant Endodontist, Shri Ganesh Dental & Maxillo-Facial Clinic, Rohtak, Haryana

---

## ABSTRACT

A natal tooth is that which is present in the oral cavity at the time of birth. The incidence of natal teeth is approximately 1:2000 to 1:3000 live births. The most commonly affected teeth are the lower primary central incisors. They might resemble normal primary deciduous teeth in size and shape, but are often smaller in size with hypoplastic enamel and dentin; with poor or absent root formation. Most common complication resulting due to natal teeth includes discomfort during suckling, tongue ulceration, laceration of mother's breasts and even aspiration of teeth. Natal teeth should be differentiated from primary or supernumerary teeth. A dental radiograph is indicated for differentiation. Extraction of tooth is indicated if tooth is excessively mobile or if it is supernumerary. The purpose of this paper is to highlight important aspect of natal teeth and to upgrade the knowledge of dental Surgeons regarding the management of these teeth.

**Key words:** Natal teeth, Neonatal teeth, Predeciduous teeth, supernumerary teeth, Rega-Fede Disease, Eruption cyst.

---

## INTRODUCTION

The normal eruption of the primary teeth typically begins at the six months of age<sup>[1]</sup>. Sometimes accessory teeth may be found at or shortly after birth. Historically, teeth that are present at the time of birth in the new-borns have been termed as natal teeth while those arising within the first 30 days of life are designated as neonatal teeth<sup>[2]</sup>. This is an artificial distinction and it appears appropriate to call all these teeth "natal teeth". Various terms have been used to designate these teeth like congenital teeth, fetal teeth, premature teeth, predeciduous teeth, precociously erupted teeth and dentitia praecox & dens connatalis<sup>[3]</sup>. In the past, because of its rare occurrence, the natal teeth were associated with superstition and being related to good or bad omens. Today, these teeth are also the topic of concern for both health professionals and parents because of their mobility and chances of being swallowed or aspirated by infants during feeding. This article reviews the etiology, clinical features, complications and management of natal teeth.

## REVIEW OF LITERATURE:

The natal teeth have been a subject of curiosity and study since the beginning of the time, being surrounded by the belief and assumptions. These were reported by the Titus Livius in 59B.C. He considered natal teeth to be a prediction of the disastrous events<sup>[17]</sup>. Caius Plinius Secundus (23 B.C.) believed that a splendid future awaited male infant with natal teeth whereas the same phenomenon was a bad omen for girls<sup>[17]</sup>. They were described in the cuneiform inscriptions found at Nineveh in 19<sup>th</sup> century<sup>[6, 7]</sup>.

Superstitions and folklore about natal teeth have varied from claims that affected children were exceptionally favoured by the belief that were doomed. In India, Africa, Poland and China, affected children were considered monsters and bearers of misfortune<sup>[18]</sup>. Moreover in many African Tribes affected children were murdered soon after birth because they were believed to bring misfortune to all they would contact<sup>[17]</sup>.

Chinese believed when a baby with natal teeth that starts to bite, one of the parents would die<sup>[17]</sup>. Alwright reported a Chinese patient in whom extraction was required so that the tooth together with the "Attending evil spirit" could be disposed of in the middle of Honk Kong Harbor<sup>[18]</sup>.

In England, the belief was that babies born with teeth would grow to be famous soldiers whereas in France and Italy the belief was that this consideration would guarantee the conquest of the world<sup>[4]</sup>. Historians such as Richard, Zoroaster, Hannibal, Mazann, Luis, Richeliev, Mirabeau and Napoleon may also have been favoured by the presence of natal teeth<sup>[17]</sup>.

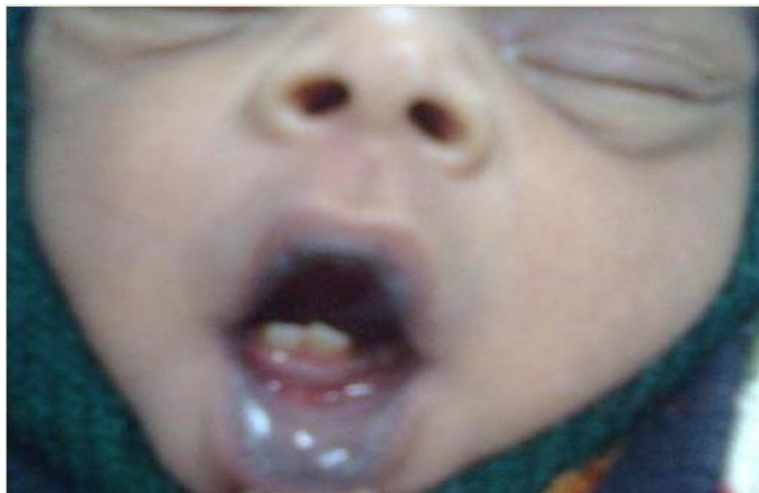## ETIOLOGY

The exact etiology behind the development of natal teeth is not clear. Infection, trauma, malnutrition, superficial position of tooth germ, maternal exposure to environment toxins, febrile states, hereditary transmission of a dominant autosomal gene, hypovitaminosis have been implicated as causative factors<sup>[4, 5]</sup>. Some authors suggest that natal teeth may be associated with some syndromes such as chondroectodermal dysplasia (Elis-Van Creveld), Hallerman-Streiff Syndrome (Oculomandibulofacial Dysplasia) Pierre Robin Syndrome, Sotos syndrome, congenital pachyonychia and craniofacial dysostosis<sup>[1, 6, 7, 8]</sup>. Natal teeth are present in 2% of infants with unilateral cleft and palate and 10% of infants with bilateral cleft lip and palate<sup>[9]</sup>. Also, there are two school of thought regarding natal teeth, one suggests that the accessory dental organs separates from the deciduous dental lamina and drift into the oral epithelium while other says that there is a pre-deciduous dental lamina that forms dental organs that lie superficially in the mesenchyme which become separated and develop within the oral epithelium<sup>[13]</sup>. Some authors have suggested that these teeth may represent pre-deciduous supernumerary teeth and most are prematurely erupted deciduous teeth.

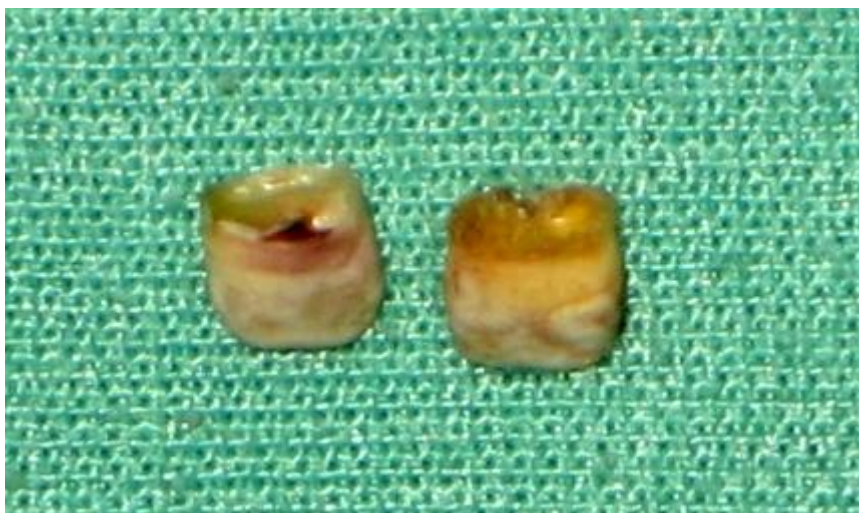## CASE REPORT-1

A two weeks old baby girl was brought to the clinic by her grandmother complaining of two erupted lower front teeth since birth. Otherwise she was a healthy infant. On intraoral examination, two mandibular anterior teeth (Fig 1A) were found. The Teeth were mobile and caused discomfort for the nursing mother and at the same time presented a potential risk for aspiration to the infant, therefore, their removal was planned.

After applying topical anaesthesia to the adjacent gingiva, a piece of gauge placed lingual to the natal teeth to prevent the aspiration, teeth were extracted (Fig.1B).



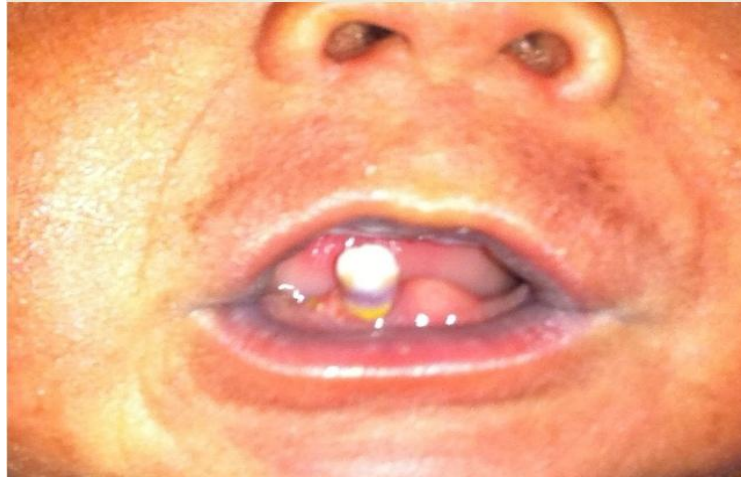**Figure 1: A**Clinical view of natal teeth in oral cavity.



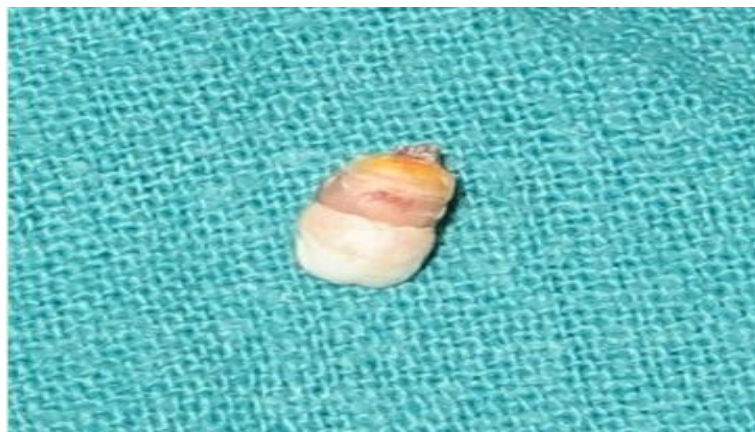**Figure 1: B**Extracted Natal teeth showing shell shaped crown with no root formation. Teeth are yellowish in colour with hypoplastic enamel and dentin.

## CASE REPORT-2

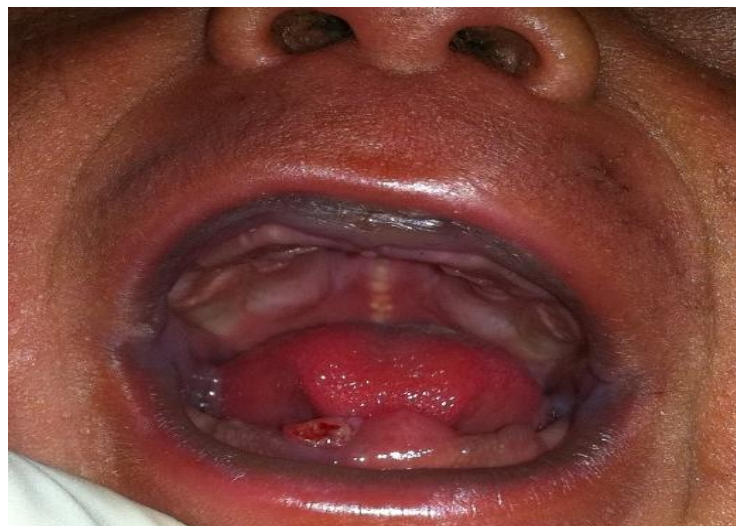A twelve days old baby girl was brought to the clinic by her parents with the complaint of one erupted lower front tooth since birth. Intraoral examination revealed a single mandibular anterior tooth (Fig.2A). Another tooth was palpable over the alveolar mucosa (Fig 2A). The tooth was excessively mobile and caused discomfort to the baby while feeding. Ulceration of the tip of tongue was also present. So, the mobile tooth was extracted under topical anaesthesia (Fig.2B). The Tooth below alveolar mucosa was left untouched (Fig2C).



**Figure 2: A Clinical view of natal tooth with gingival swelling adjacent to it.**



**Figure 2: B Extracted natal tooth with very little root formation.**

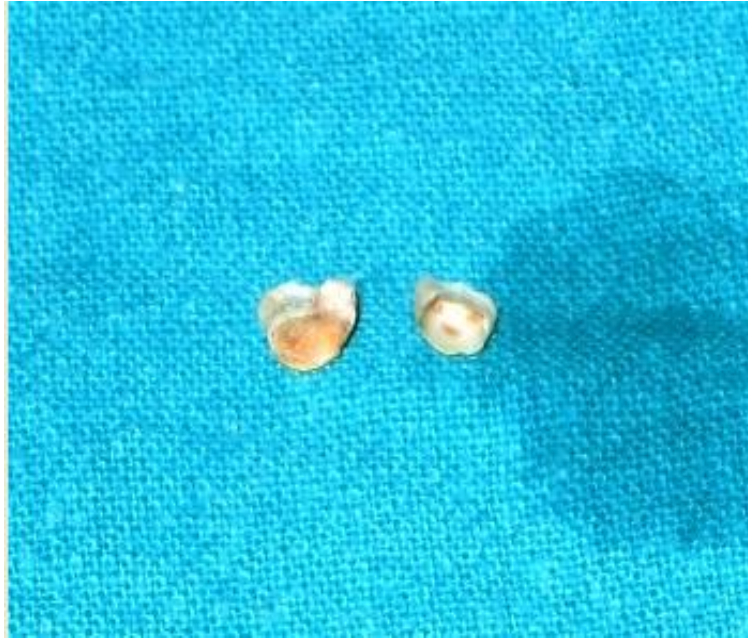

**Figure 2: C Post extraction view.**



### CASE REPORT-3

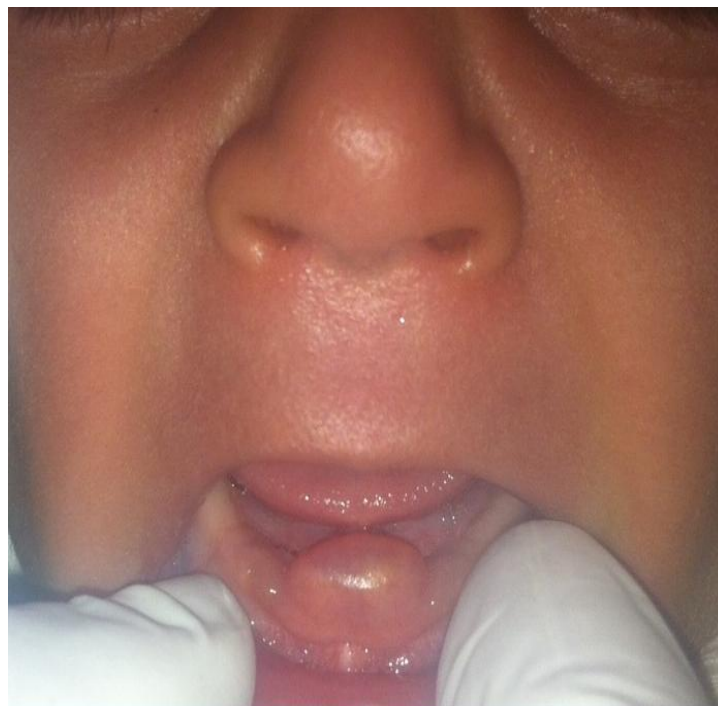
A fifteen days old baby boy was brought to the clinic by his parents with the complaint of two erupted lower front teeth since birth. On the intraoral examination, two mandibular anterior teeth were found. The teeth were excessively mobile and at the verge of fall. So, the teeth were extracted immediately under topical anaesthesia (Fig.3).



**Figure 3: Extracted shell shaped natal teeth without root formation.**

### CASE REPORT-4

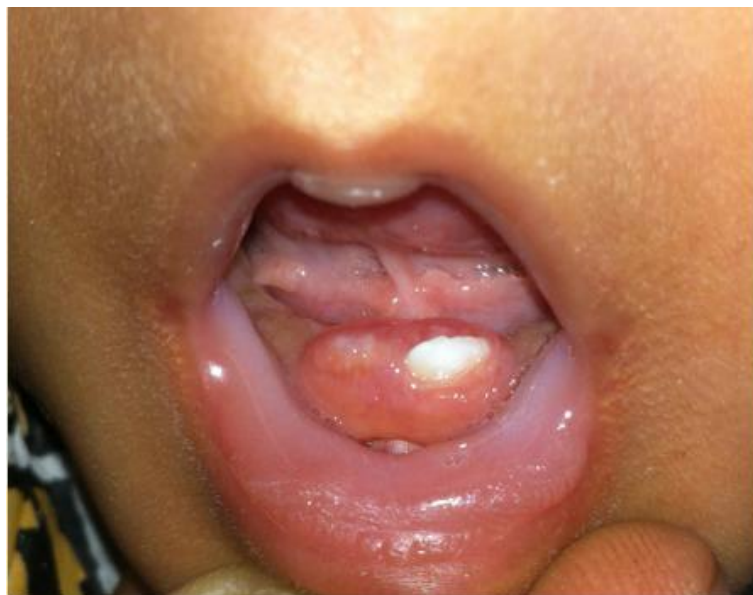A two week old baby boy was brought to the clinic by his parents with the chief complain of swelling in lower jaw, causing difficulty in feeding (Fig.4A). Intra-oral periapical x-ray (Fig 4B) was done which confirmed two teeth buds in the swelling. Fine Needle Aspiration Cytology (FNAC) was carried out from the swelling. FNAC resulted in reduction in swelling exposing incisal edge of two teeth (Fig.4C). But after one week mother came back with complain that teeth are hurting while feeding as well as they are highly mobile too; therefore, their extraction was done (Fig 4D).



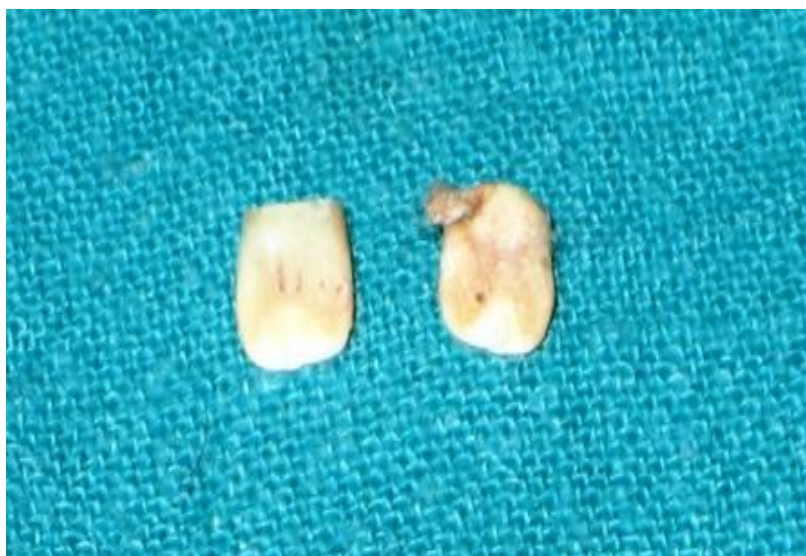**Figure 4: A 1.5 x 1.0 cm eruption cyst over alveolar ridge of mandible.**



**Figure 4: B IOPA X Ray showing two teeth**



**Figure 4: C Erupting natal tooth of third quadrant.**



**Figure 4: D Extracted teeth.**

## CLINICAL ASPECTS

These teeth are usually small in size and shape and lie in the soft tissues overlying the alveolar ridge without stabilizing bone. Most natal teeth are mobile. They might resemble normal primary teeth in shape and size; however, the teeth are often smaller in size and yellowish in colour (Fig. 1B) and have hypoplastic enamel and dentin with poor or no root formation (Fig. 1B). Usually only one or two teeth erupts early and most often the deciduous mandibular incisors. Approximately 85% of natal teeth are mandibular incisors, 11% are maxillary incisors and 4% are posterior teeth<sup>[3]</sup>. According to Kates & colleagues 95% of the natal teeth were normal primary incisor and 5% were supernumerary incisors<sup>[10]</sup>. There is no difference in the prevalence between males and females; however there is slight female (66%) predilection<sup>[10]</sup>.

Clinically such teeth can be classified as mature (when they are fully developed in shape and comparable in morphology to the primary teeth) and immature (when their structure & development are incomplete) and have poor prognosis for retention<sup>[4]</sup>.

On the basis of appearance and literature data, Hebling in 1997 classified each natal tooth into four clinical categories<sup>[11]</sup>.

1. Shell shaped crown, poorly fixed to the alveolus by gingival tissue and absence of a root (Fig.3).
2. Solid crown, poorly fixed to the alveolus by gingival tissue and little (Fig.2B) or no root (Fig 1B).
3. Eruption of incisal margin of the crown through gingival tissues (4B).
4. Edema of gingival tissue with an unerupted but palpable tooth (Fig 2A).

More than 2-mm of mobility found in 1<sup>st</sup> and 2<sup>nd</sup> categories and usually required extraction. Natal tooth has been associated with soft tissue growths like pyogenic granuloma, peripheral ossifying fibroma and eruption cyst (Fig.4A). Sometimes causes traumatic ulceration of adjacent soft tissues especially anterior and ventral surface of tongue. This traumatic ulceration of tongue is known as Riga-Fede disease as histologically described by Riga and Fede<sup>[12]</sup>. This lesion typically found between the one week and one year of age.

## DISCUSSION

Normally deciduous teeth begin to erupt in oral cavity at the age of 6months. In rare cases, this chronology of tooth eruption is significantly altered and first teeth are present at birth. According to the definition presented by Massler and Savara(1950), taking only the time as reference, natal teeth are those that erupt in oral cavity at the time of birth and neonatal are those that erupts during the first 30days of life<sup>[2]</sup>. The incidence of natal teeth ranges from 1:2000 to 1:3500 live births<sup>[6, 7 and 10]</sup>. These teeth in most cases represent the deciduous dentition and their removal should not be done hastily. A dental radiograph should be used to differentiate the premature eruption of a primary tooth from a supernumerary tooth<sup>[4, 6]</sup>. The major problems arising from natal teeth are discomfort during suckling, laceration of the mother's breast, sublingual laceration with refusal to feeding and even aspiration of teeth.

Natal teeth must be approached individually, with sound clinical judgement guiding appropriate therapy. If the teeth are mobile and at risk for aspiration, then their removal is indicated and if mobility is not a problem and teeth are stable, then they should be retained. Traumatic ulceration of adjacent soft tissues may occur during breast feeding but often can be resolved with appropriate measures. The decision for maintaining these teeth in oral cavity depends on some factors like degree of mobility, inconvenience during suckling, interference with breast feeding, possibility of traumatic injury and whether the tooth is part of the normal dentition or is supernumerary. The maintenance of these teeth in the mouth is the first treatment option, unless this would cause injury to the baby. The detection of Riga-Fede disease is also an indication of tooth extraction.

If the treatment option is extraction, this procedure should not pose any difficulty since these teeth can be removed using forceps or even with the fingers using piece of gauge and firm pressure without the need for anaesthesia. But some authors emphasized the precaution that should be taken when extracting natal teeth especially avoiding extraction up to 10<sup>th</sup> day of life to prevent haemorrhage, avoiding unnecessary injury to the gingiva, health of the infant. Berendsen and Wakkerman mentioned the risk of haemorrhage in extractions done before 10days of life when vitamin-K was not administered<sup>[14]</sup>.

This waiting period is due to need to wait for the commensal flora of the intestine to become established and produce Vitamin-K, which essential for the production prothrombin in the liver. Hence it is safer to wait until a child is 10days old before extracting tooth. If it is not possible to wait then it is advisable to evaluate the need for administration of Vitamin-K with a paediatrician, if the new born is not medicated with Vitamin-K immediately after birth<sup>[4, 15]</sup>. Now a day, Vitamin-K is administered intramuscularly to the baby as a part of immediate medical care to prevent haemorrhagic disease of the new-born<sup>[4, 15]</sup>. Extraction of natal teeth should be followed by curettage of the socket to



prevent development of the cells of the dental papilla, as it could result in eruption of tooth like structures several months later<sup>[16]</sup>. Periodic follow up by the pedodontist is recommended to avoid any complication.

### CONCLUSION

Natal teeth are rarely found entity in oral cavity and usually cause no harm. The decision to keep them or extraction should be evaluated in each case. If possible radiograph should be taken to differentially diagnose between supernumerary teeth and actual normal primary teeth. When teeth are supernumerary they should be extracted. If teeth are to be preserved, then regular follow up by a dentist especially paediatric dentist is recommended. Parents should be informed regarding the maintenance of good oral hygiene of the baby. Hence early diagnosis and adequate treatment should be of prime concern in the management of natal teeth to avoid any complication

### REFERENCES

- [1]. Uzamis M, Omlmez S, Ozturk H, et al. Clinical and ultrstructural study of natal and neonatal teeth. J Clin Pediatr dent. 1999; 23:173-177.
- [2]. Masslerr M, Sanara BS. Natal & neonatal teeth: a review of twenty four cases reported in the literature. J Pediatr 1950; 36: 349-359.
- [3]. Zhu J. and King D. "Natal and neonatal teeth". J Dent Child. 1995; 23:123-128.
- [4]. Cunha RF, Boer FAC, Torriani DD, et al. Natal and neonatal teeth: review of the literature. American academy of Pediatric Dentistry. 2001; 23:158-162.
- [5]. Gladen BC, Taylor JS, Wu YC, et al. Dermatology finding in children exposed transplacently to heat-degraded polychlorinated biphenyls in Taiwan. Br. J Dermatol. 1990; 122:799-808.
- [6]. Leung AK. Natal teeth. American Journal of Disease of Children. 1986; 140:249-251.
- [7]. Seminario AL, Ivancakova R. Natal and neonatal teeth. Acta Medica. 2004; 47:229-233. To EWH. A study of natal teeth in Hong Kong Chinese. Int J Paediatr Dent. 1992; 2:73-76.
- [8]. Marakoglu K, Percin EF, Marakoglu I, et al. Anencephalic infant with cleft palate and natal teeth: a case report. Cleft palate Craniofac j. 2004; 41:456-458.
- [9]. De Almeida CM, Gomide MR. Prevalence of natal/neonatal teeth: case report. Cleft Palate J. 1996; 33:297-299.
- [10]. Kate GA, Needleman HL, Holmes LB. Natal and neonatal teeth: a clinical study. J Am Dent Assoc. 1984; 109: 441-443.
- [11]. Hebling J, Zuanon ACC, Vianna DR. Dente Natal-A case of natal teeth. Odontol Clin 7:37-47, 1997.
- [12]. Amberg S. Sublingual growth in infants. Am J Med Sci 126:257-269, 1903
- [13]. Shafer WG, Hine MK, and levy BM. "A text book of oral pathology". 4<sup>th</sup> Edition, W.B. Sunder's Company, Philadelphia, PA. 1993. Pg. 360 and 785.
- [14]. Berndsen WJH, Wakkerman HL. Continued growth of the papillae after extraction of neonatal teeth: report of case. Dent Child 55:139-141, 1088.
- [15]. Leone RC, Araujo MCK. Doenca hemorragica do recém-nascido. In: Pediatria basica. 8a Ed. Sao Paulo: Sarvier; 1994:430-431.
- [16]. Ooshima T, Mihara j, Saito Tand sobue s. "Eruption of tooth like structures following exfoliation of natal tooth: report of case." J Dent Child. 1986; 53:275-278.
- [17]. Bodenhoff J, Gorlin RJ. Natal and neonatal teeth: Folkware and fact. Pediatr 32:1087-1093, 1963.
- [18]. Allwright WC. Natal and neonatal teeth. British Dent J 105:163-172, 1958.