

# Reconstructing the Lost Function: Rehabilitation of a Partial Maxillectomy Patient with Unconventional Maxillary Cast Partial Denture: A Case Report

Dr. Anamika Ahlawat<sup>1</sup>, Dr. Divya Dahiya<sup>2</sup>, Dr. Neeraj Kumar<sup>3</sup>,  
Dr. Reena Ravi<sup>4</sup>, Dr. Rangesing Rathwa<sup>5</sup>

<sup>2</sup>Professor, Dept. of Prosthodontics, PGIDS, Rohtak  
<sup>1,3,4</sup> Post-Graduate Student, Dept. of Prosthodontics, PGIDS, Rohtak  
<sup>5</sup> Consultant Prosthodontist

---

## ABSTRACT

**Malignancies are common in the oral region and are treated usually through surgical intervention. Oral rehabilitation of patients with acquired defects of the maxilla presents a challenging task for the maxillofacial prosthodontist. Compromised support, retention, stability and weight are common prosthodontic treatment problems for these patients.. This case report describes a predictable and simple technique to fabricate a cast partial maxillary resection prosthesis in a rehabilitation of a maxillary defect (Aramany's class I).**

**Key Words: Acquired maxillary defect, Maxillary resection prosthesis,**

---

## INTRODUCTION

Acquired defects of the maxilla may result from pathological changes, trauma, or after surgical resection of oral neoplasms. These defects pre-dispose the patient to difficulty in swallowing, mastication, fluid leakage into the nasal cavity and hypernasal speech[1]. Rehabilitation of these defects not only improves speech, swallowing and mastication, but also it has a great role in improving the quality of patient's life[2]. Major goal of cancer therapy is not only to eradicate the disease but also to restore patients to a reasonably normal quality of life[3],[4]. Psychological well-being and patient's vitality are an increasing contribution to evaluation of success of maxillectomy patients [5].

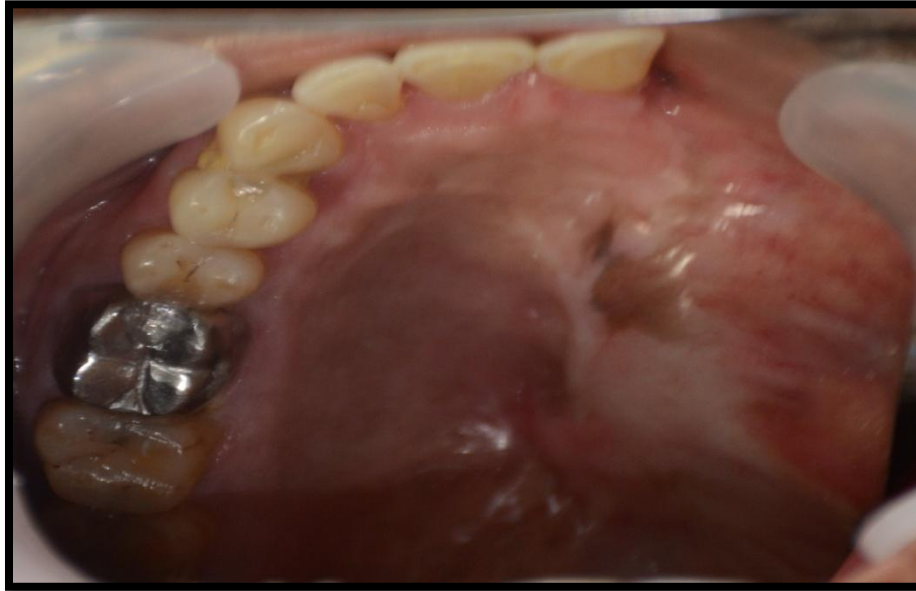Oral rehabilitation of patients with acquired defects of the maxilla present a challenging task for the maxillofacial prosthodontist. Compromised support, retention, stability and weight of the prosthesis are common prosthodontic treatment problems for these patients. In partially edentulous patients support, stability and retention of a removable maxillary resection prosthesis relies on the remaining hard and soft tissues[2],[6]. The larger the surgical resection, the greater the loss of the mucogingival support, which in turn results in increased unfavorable forces acting on the remaining abutment teeth[6].

Traditional, maxillary resection prosthesis have been used to occlude areas of the palate that have been resected to restore esthetics and to diminish difficulties associated with mastication, swallowing and speech intelligibility.[7] The advantages of maxillary resection prosthesis include immediate rehabilitation and less procedure time. The surgical site can be easily examined after removing the prosthesis, and tumor recurrence, if any, may be detected in time. Maxillary resection prosthesis may therefore still be the privileged treatment modality after maxillectomy.[8] [9]

It is clinically important to evaluate the oral function such as mastication, swallowing and estimate the improvement provided by maxillary resection prosthesis.[10][11][12]

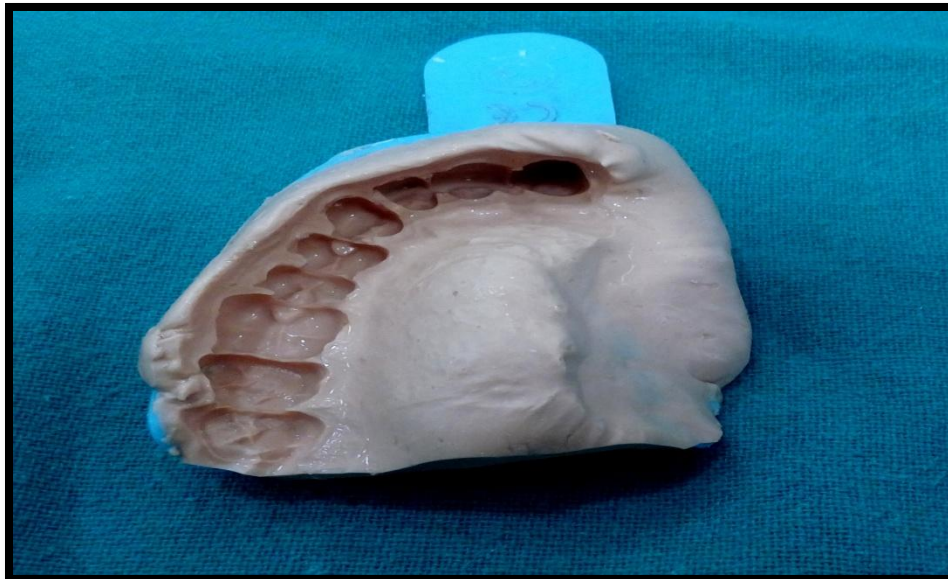
### CASE REPORT

A 45 years old male patient was referred from Oral & Maxillofacial Surgery department with a history of partial maxillectomy 6 month back to the Prosthodontics and Crown & Bridge department for prosthetic rehabilitation (Fig 1).



**Fig. 1: Pre-Operative Intraoral View**

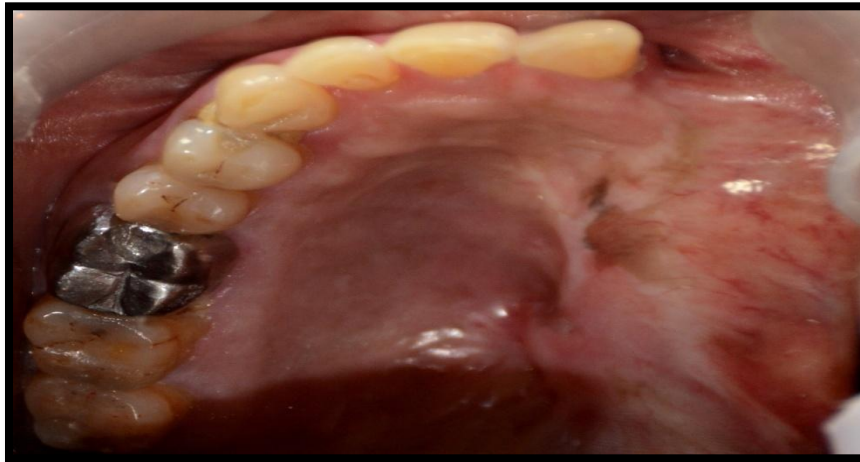The defect was more like Aramany class I. Maxillary and mandibular preliminary impressions were made with irreversible hydrocolloid (Zelgan, Dentsply) (Fig 2) and poured in Type 3 gypsum product (Kalabhai, Kaldent) to obtain diagnostic casts.



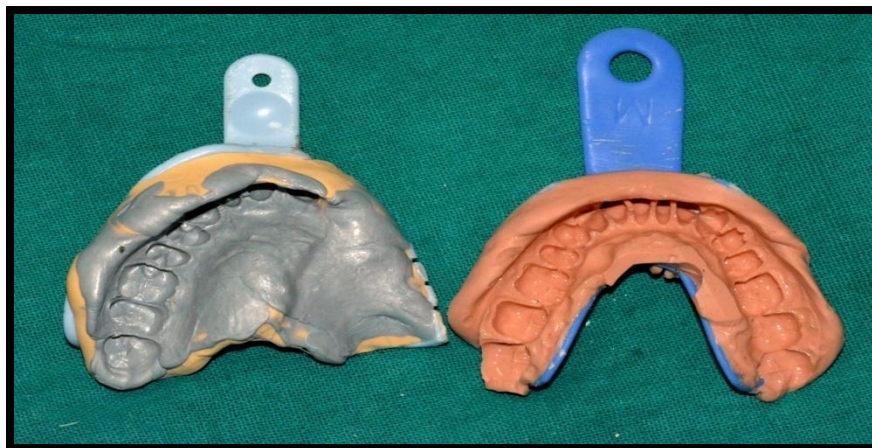**Fig. 2: Diagnostic Impression**

- Diagnostic casts were surveyed, and a cast partial framework was planned with the following components: Embrasure clasps in relation to 15, 16 ; occlusal rest on 14, 15 and 16, cingulum rest on 13, I bar was planned on 21. Modified complete palatal type of major connector extended till palatal surfaces of teeth. Distal surface of 21 was also prepared to act as a guiding plane

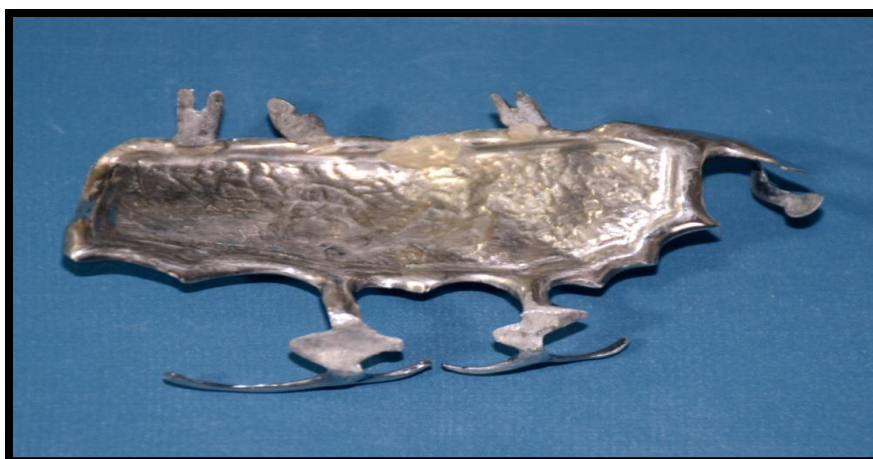• Mouth preparation was done (Fig 3). Border molding was done towards the defect side and final impression was made with polyvinylsiloxane impression material (Affinis, Coltene Whaledent) (Fig 4) and master cast was then poured in die stone (kalabhai, Ultrastone). Wax pattern was adapted on refractory cast and casting of metal framework was carried out(Fig 5). Trial of finished and polished framework and needed adjustments were done (Fig 6)



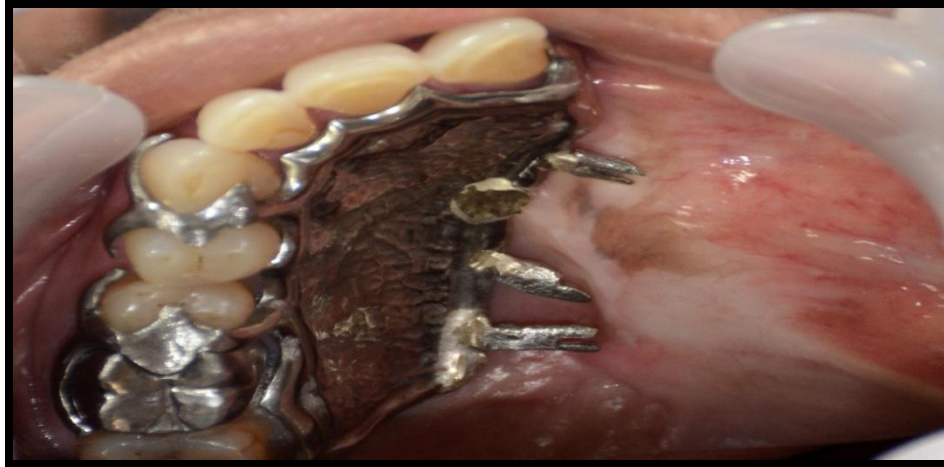**Fig. 3: Intraoral View after Mouth Preparation**



**Fig. 4: Final Impression, Putty with Light Body**

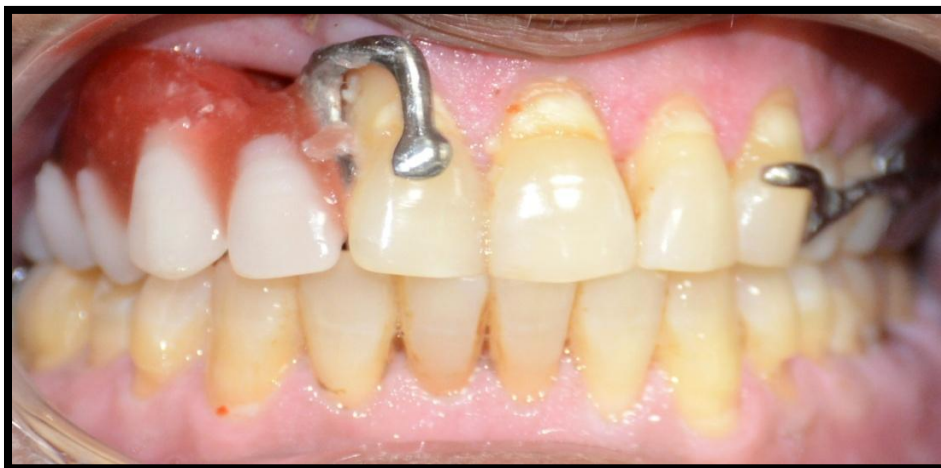

**Fig. 5: Cast Partial Framework Obtained After Casting**

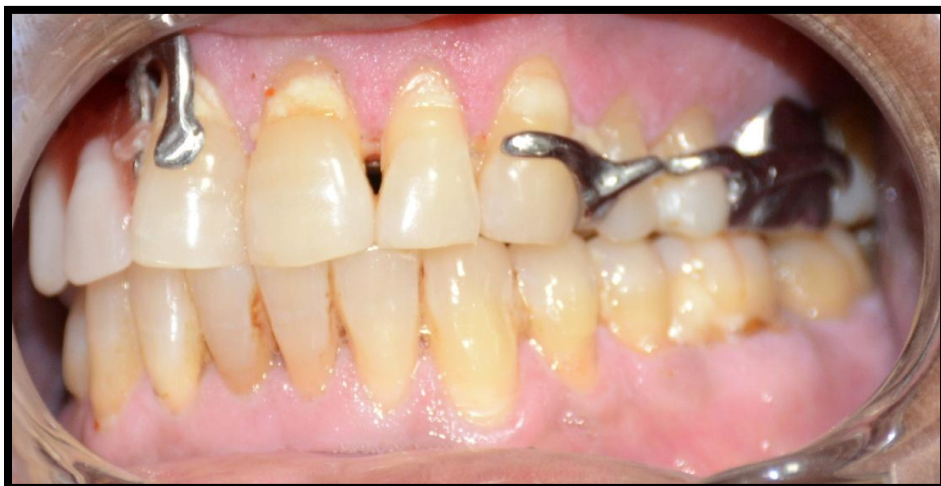

**Fig. 6: Framework Try In**

- Jaw relations were recorded and try in done (Fig 7a & 7b). After try in patient's speech was assessed by speech pathologist.

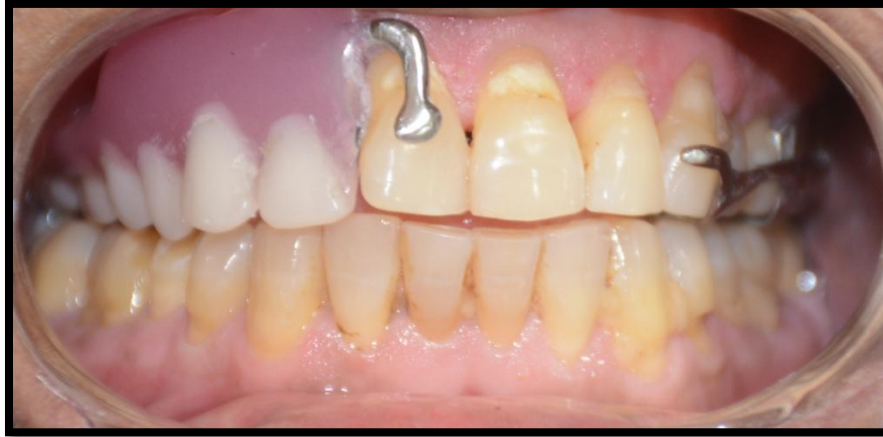

**Fig. 7a: Wax Try-In**

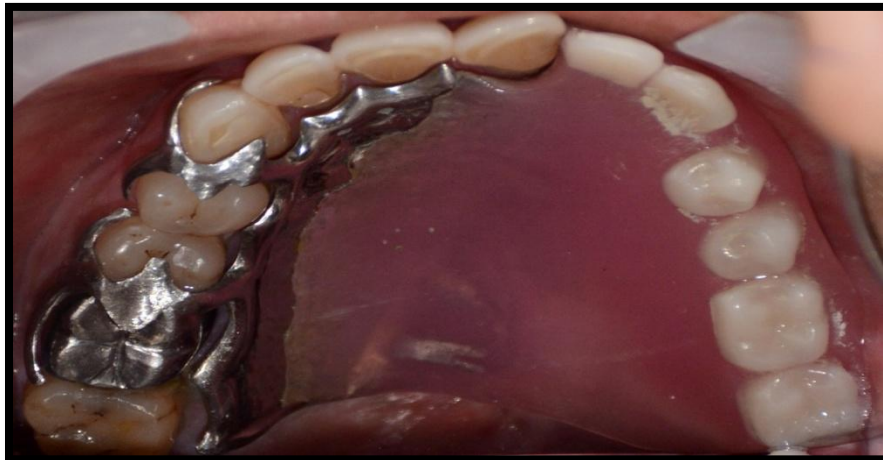

**Fig. 7b: Wax Try-In**

- Final prosthesis was adjusted in the patient's mouth and occlusal adjustments were done to make passive contacts on defect side (Fig 8a & 8b). Prosthesis was functionally and esthetically pleasing (Fig 9 & 10).



**Fig. 8a: Insertion of the Finished Prosthesis**



**Fig. 8b: Insertion of the Finished Prosthesis**



**Fig. 9: Pre Operative Frontal View**



**Fig. 10: Post RPD Insertion Extra Oral Frontal View**

- Post insertion follow-up and patient care were carried out for a period of one year, which revealed that the patient was satisfied and comfortable with the functioning of the prosthesis. There was appreciable improvement in patient's speech and appearance, leading to attenuation of the sequelae of tumor resection.

### **DISCUSSION**

In this technique, cast metal framework was fabricated which lightened the weight and improved retention, stability and support of the prosthesis aiding in improved speech and swallowing. The goals of successful rehabilitation are to restore normal deglutition and speech by improving palatal contours and further improving the mid-facial aesthetics by supporting the soft tissues, replacing the missing dentition, improving retention, stability and support without compromising the health of residual dentition and supporting tissues[2],[6]. Prosthetic rehabilitation of the dentate maxillectomy patient is a lengthy and time involved process. These goals can be achieved when good communication exists between surgical, prosthodontics and speech colleagues.

### **CONCLUSION**

Prosthodontic rehabilitation of complex maxillectomy defects improves not only oral intake of food and appearance but also speech. It also plays an important role in improving swallowing abilities and psychological status.

### **REFERENCES**

- [1] Beumer J, Curtis T, Marunick M. Maxillofacial rehabilitation: Prosthodontic and surgical considerations. St Louis: Ishiyaku EuroAmerica, Inc.;1996.p.399-402.
- [2] Lang BR, Bruce RA. Presurgical maxillectomy prosthesis. J Prosthet Dent 1967;17(6):613-9.
- [3] Rottner K, Richter EJ. Effect of occlusal morphology on the accuracy of bite force measurements using thin film transducers. Int J Prosthodont 2004;17:518-23.
- [4] King GE, Gay WD. Application of various removable partial denture design concepts to a maxillary obturator prosthesis. J Prosthet Dent 1979;41:316-8.
- [5] Irish J, Sandhu N, Simpson C, Wood R, Gilbert R, Gullane P, Brown D, Goldstein D, Devins G, Barker E. Quality of life in patients with maxillectomy prostheses. Head Neck 2009;31:813-21



- [6] Parr GR. Prosthodontic principles in the framework design of maxillary obturator prosthesis. *J Prosthet Dent* 1989;62(2):205-12.
- [7] Aramany MA. Basic principles of obturator design for partially edentulous patients Part I: Classification. *J Prosthet Dent* 1978;40: 554-57.
- [8] Aramany MA. Basic principles of obturator design for partially edentulous patients Part II: Design principles. *J Prosthet Dent* 1978;40:656-62.
- [9] Eric SA, Jason JP, John DP, Robert FW. Technique for quick conversion of an obturator into a hollow bulb. *J Prosthet Dent* 2001;85(4):401-8.
- [10] Matsuyama M, Tsukiyama Y, Koyano K. Objective clinical assessment of change in swallowing ability of maxillectomy patients when wearing obturator prostheses. *Int J Prosthodont* 2005;18:475-9.
- [11] Vero N, Mishra N, Singh B, Singh K, Jurel S, Kumar V. Assessment Of Swallowing And Masticatory Performance In Obturator Wearers: A Clinical Study. *J Adv Prosthodont* 2015;7:8-14
- [12] Jain S, Aggarwal A, Shetty S. An Innovative Technique For Fabrication Of A Hollow Maxillary Resection Prosthesis: A Case Report. *Indian Journal of Dental Sciences*. December 2014 Issue:5, Vol.:6