

Combined Negative Pressure Wound Therapy and Ayurvedic Vrana Chikitsa in the Management of a Complex Post-Traumatic Gluteal Wound: A Case Report

Dr. Afrin Dawal Mulani¹, Dr. Amit Ramchandra Shedge²

¹PG Scholar, Department of PG Studies In Shalyatantra, LRP Ayurvedic Medical College & PG Research Institute, Urun, Iswarpur, Sangli.

²Guide, Professor & HOD, Department Of PG Studies In Shalyatantra, LRP Ayurvedic Medical College & PG Research Institute, Urun, Iswarpur, Sangli.

ABSTRACT

Background: Large traumatic wounds complicated by tissue necrosis and infection often present considerable challenges in clinical practice. Delayed healing may prolong hospitalization, increase treatment costs, and adversely affect a patient's physical and psychological well-being. While Negative Pressure Wound Therapy (NPWT) has become an important component of modern wound management, traditional Ayurvedic wound-care practices continue to be utilized for promoting local tissue repair. Evidence describing the combined application of these approaches remains limited.

Case Presentation: A 48-year-old man developed a non-healing wound over the left gluteal region following a road traffic accident. The injury was initially associated with severe soft-tissue contusion and abrasion but subsequently progressed to necrosis with persistent wound discharge. On presentation, the wound measured approximately 15 × 10 cm and was characterized by unhealthy tissue, slough, local inflammation, and offensive discharge. From an Ayurvedic perspective, the wound exhibited features consistent with Dushta Vrana, including Srava, Daha, Durgandha, and delayed tissue recovery.

Intervention: Management involved surgical debridement followed by the application of NPWT to establish a healthy wound environment and encourage granulation tissue formation. Ayurvedic wound-care measures were incorporated during treatment and included cleansing with Triphala Kashaya and local application of Jatyadi Taila and Madhu. Supportive internal Ayurvedic medications were administered as part of the overall treatment strategy.

Outcome: Sequential clinical assessment demonstrated progressive improvement in wound condition, including reduction in slough, discharge, pain, and local inflammatory changes. Healthy granulation tissue developed during follow-up, followed by wound contraction and gradual epithelialization. No evidence of secondary infection was observed, and the wound became suitable for further reconstructive management.

Conclusion: This case illustrates the successful management of a complex post-traumatic wound using an integrative treatment model that combined modern NPWT with Ayurvedic wound-care principles. The observed clinical improvement suggests that such an approach may serve as a useful adjunct in selected cases of difficult-to-heal wounds. Further systematic investigations are required to evaluate its broader clinical applicability.

Keywords: traumatic wound, negative pressure wound therapy, vacuum-assisted closure, Dushta Vrana, Jatyadi Taila, Triphala Kashaya, integrative wound management, Ayurveda.

INTRODUCTION

Traumatic wounds are frequently complicated by tissue loss, infection, and delayed healing. Negative Pressure Wound Therapy (NPWT) promotes granulation tissue formation, removes exudate, and improves wound contraction. Ayurvedic

literature describes chronic infected wounds as Dushta Vrana and recommends Vrana Shodhana and Vrana Ropana therapies. This report presents an integrative approach combining VAC therapy with Ayurvedic wound management.

Demographic and Clinical Characteristics Of Patient -

Table Demographic and Clinical Characteristics of the Patient

Parameter	Findings
Age	48 years
Sex	Male
Mode of Injury	Road traffic accident resulting in blunt soft-tissue trauma
Affected Region	Left lateral gluteal region
Chief Complaint	Non-healing wound with persistent discharge and pain
Duration Before Presentation	Approximately 3 days after injury
Initial Clinical Condition	progressive tissue necrosis despite primary wound care
Comorbidities	No significant comorbid illness reported
History of Diabetes Mellitus	Absent
History of Hypertension	Absent
Peripheral Vascular Disease	Absent
Immuno compromised State	Not reported
Smoking History	No history of smoking
Alcohol Consumption	Occasional
Drug Allergy	No known drug allergy
General Condition at Admission	Hemodynamically stable
Local Pain	Present
Foul-Smelling Discharge	Present
Difficulty in Sitting and Ambulation	Present
Systemic Signs of Infection	Absent
Neurovascular Status of Affected Limb	Intact
Wound Type	Traumatic contused wound with secondary necrosis
Approximate Wound Size	15 × 10 cm
Wound Margins	Irregular and edematous
Wound Bed	Necrotic tissue with slough
Wound Discharge	Seropurulent
Surrounding Skin	Inflamed but viable
Clinical Evidence of Local Infection	Present
Ayurvedic Diagnosis	Dushta Vrana
Predominant Dosha Involvement	Pitta-Kapha predominance with associated Vata involvement
Affected Dhatu	Mamsa and Rakta
Key Ayurvedic Features	Srava, Daha, Durgandha, Vedana, and delayed wound healing
Consent for Publication	Written informed consent obtained

**Clinical findings –
General Examination -**

Parameter	Value
Pulse Rate	84/min
Blood Pressure	126/80 mmHg
Respiratory Rate	18/min
Temperature	Afebrile
SpO ₂	98%

Systemic examination revealed no significant abnormalities.

**Local Examination -
Modern Assessment**

Parameter	Finding
Site	Left lateral gluteal region
Size	15 × 10 cm
Shape	Irregular
Margins	Edematous
Floor	Necrotic tissue and slough
Discharge	Seropurulent
Tenderness	Present
Odour	Present
Surrounding Skin	Inflamed but viable

Ayurvedic Assessment

Diagnosis - Dushta Vrana
 Dosha Involvement -Pitta ,Kapha ,Vata (secondary)
 Dushya - Rakta,Mamsa
 Srotas-Raktavaha Srotas, Mamsavaha Srotas
 Agni-Samagni
 Bala-Madhyama Bala
 Vrana Lakshana -Srava,Daha,Vedana,Durgandha,Manda Ropana

Diagnostic Assessment

Laboratory Findings-

Investigation	Result
Hemoglobin	13.2 g/dL
Total Leukocyte Count	12,800/mm ³
Differential Count	Neutrophilic predominance
Platelet Count	Normal
ESR	Elevated
Random Blood Sugar	104 mg/dL
Serum Creatinine	0.9 mg/dL
Serum Electrolytes	Within normal limits

Microbiological Assessment-

Wound swab culture demonstrated mixed bacterial growth sensitive to piperacillin-tazobactam.

Radiological Assessment-

MRI pelvis revealed soft-tissue involvement without osteomyelitis or neurovascular injury.

Therapeutic Intervention

Surgical Intervention -

Debridement

Extensive surgical debridement was performed under spinal anesthesia to remove all necrotic and infected tissue.

VAC Therapy

Parameter	Value
Pressure	-125 mmHg
Mode	Continuous
Dressing Change	Every 72 hours
Number of Cycles	5
Total Duration	21 days

Ayurvedic Assesment -

Ayurvedic Local Therapy

Triphala Kashaya Prakshalana

Frequency: Daily

Purpose: Vrana Shodhana

Antimicrobial action

Reduction of inflammation

Jatyadi Taila

Frequency: During VAC-free intervals

Purpose: Vrana Ropana, Granulation enhancement, Tissue regeneration

Madhu

Purpose: Lekhana, Antimicrobial effect, Moist wound healing

Internal Ayurvedic Medicines

Drug	Dose	Duration
Guduchi Ghana Vati	500 mg BD	30 days
KaishoreGuggulu	500 mg TDS	30 days
GandhakaRasayana	250 mg BD	30 days

Timeline-

Day	Clinical Event
Day 0	Road traffic accident
Day 3	Hospital admission Surgical debridement
Day 7	VAC therapy initiated
Day 14	Significant reduction in discharge
Day 21	Healthy granulation tissue
Day 28	Near-complete granulation
Day 35	Suitable for flap coverage

Serial Wound Area Measurements

Table 1. Serial Wound Healing Assessment

Time Point	Length (cm)	Width (cm)	Area (cm ²)	% Reduction from Baseline
Baseline (Day7)	15	10	150	0%
Week 1	13.5	8.5	114.75	23.5%
Week 2	12	7.5	90	40.0%
Week 3	9	7.7	54	64.0%
Week 4	9	6.4	54	72.0%
Week 5	7	6	34	86.7%

Interpretation -Progressive wound contraction was observed following initiation of VAC therapy and Ayurvedic wound care. The wound area decreased by approximately 87% within five weeks.

Wound Bed Score (WBS)

Table. Wound Bed Score

Parameter	Baseline	Week 2	Week 4
Healing edges	0	1	2
Eschar	0	1	2
Granulation tissue	1	2	4
Exudate	0	1	2
Edema	1	1	2
Dermatitis	1	2	2
Callus/Fibrosis	1	1	2
Pink wound bed	0	1	3
Total Score	4/16	10/16	19/16

Bates–Jensen Wound Assessment Tool (BWAT)

Table . BWAT Assessment

Parameter	Baseline	Week 2	Week 4
Size	5	4	2
Depth	4	3	2
Edges	4	3	2
Undermining	3	2	1
Necrotic tissue type	5	3	1
Necrotic tissue amount	3	1	1
Exudate type	4	2	1
Exudate amount	5	3	1
Skin color surrounding wound	4	3	2
Peripheral edema	4	2	1
Granulation tissue	5	3	1
Epithelialization	5	3	1
Total Score	3	34	16

Interpretation -Lower BWAT scores indicate wound improvement. The score improved from 53 (severe wound status) to 16 (healing wound), indicating substantial clinical recovery.

Numeric Pain Rating Scale (NPRS)

Table 4. Pain Assessment

Time Point	Pain Score (0–10)
Baseline	8
Week 1	6
Week 2	4
Week 3	2
Week 4	1
Week 5	1

Detailed Antibiotic Protocol

Empirical Phase

Upon admission, broad-spectrum antibiotic coverage was initiated:

1.Piperacillin–Tazobactam

Dose:4.5 g IV every 8 hours

Duration:7 days

Coverage:Gram-positive organisms

Gram-negative organisms

Anaerobic bacteria

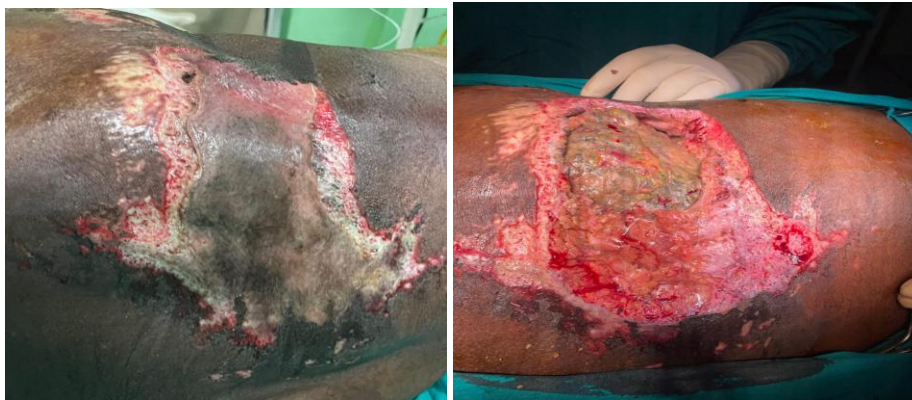2. Metronidazole

Dose: 500 mg IV every 8 hours

Duration: 5 days

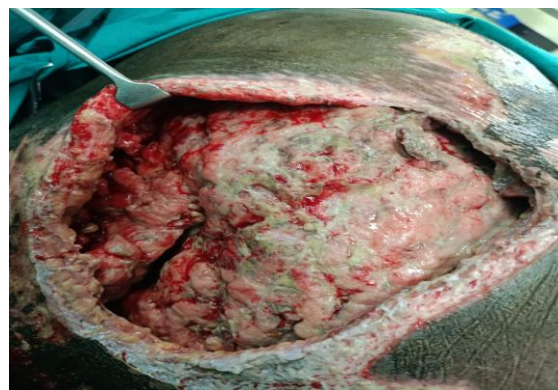
Purpose: Additional anaerobic coverage in contaminated traumatic wounds.

Wound photograph –

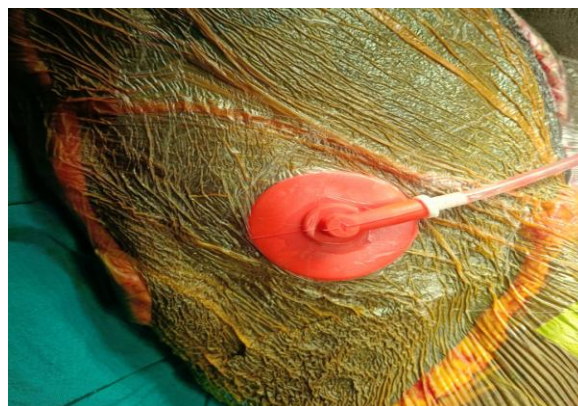

Day 3 Initial Evaluation & Debridement

- **Clinical assessment And Surgical debridement of necrotic tissue**

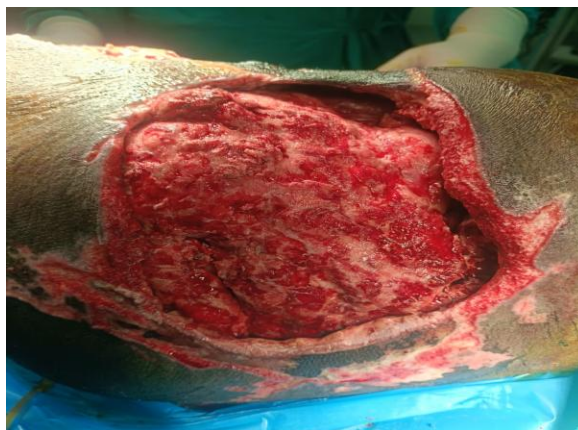

Day 7 The wound show persistent discharge, Slough, slow granulation - decided to put on VAC dressing



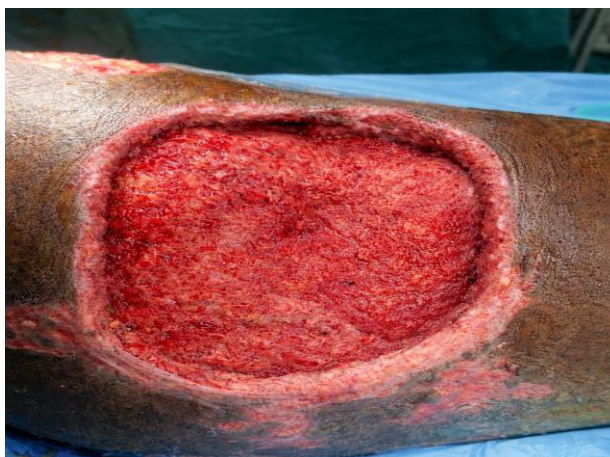Week 2 VAC Therapy Initiation

- **Negative pressure wound therapy, Reduction in slough and discharge**



Week 3-4 Healing Phase

- Healthy granulation tissue
- Slough reduction
- Margins started contracting



Week 5 Advanced Healing

- Near-complete granulation
- Margin adherence
- Progressive epithelialization

Outcome Measures And Follow up –

Parameter	Baseline	Week 2	Week 4
Wound Area (cm ²)	150	90	42
Slough (%)	90	25	5
Pain Score (VAS)	8	4	1
Discharge	Severe	Mild	Nil
Infection	Present	Controlled	Absent

Final Outcome –

Healthy granulation tissue achieved
 Significant wound contraction
 Absence of infection
 Improved mobility
 Improved pain control
 Suitable for reconstructive surgery.

Clinical Significance Section and learning point-

1. Integrative wound care may enhance healing in complex traumatic wounds.
2. Serial objective assessments improve reporting quality.
3. Ayurvedic therapies may complement modern wound-management strategies.
4. VAC therapy eliminate Kledan terminology according to Ayurveda, which promotes healing procedure.

Patient Perspective

The patient reported significant reduction in pain, discharge, and difficulty with daily activities, expressing satisfaction with treatment outcomes.

Informed Consent

Written informed consent was obtained from the patient for treatment, photography, and publication of this case report.

REFERENCES

1. Hunter JE, Teot L, Horch R, Banwell PE. Evidence-based medicine: Vacuum-assisted closure in wound care management. *Int Wound J.* 2007;4(3):256–269.
2. Webster J, Scuffham P, Stankiewicz M, Chaboyer WP. Negative pressure wound therapy for skin grafts and surgical wounds healing by primary intention. *Cochrane Database Syst Rev.* 2014;(10):CD009261.
3. Apelqvist J, Willy C, Fagerdahl AM, et al. Negative pressure wound therapy – overview, challenges and perspectives. *J Wound Care.* 2017;26(Suppl 3):S1–S113.
4. Banwell PE, Téot L. Topical negative pressure (TNP): The evolution of a novel wound therapy. *J Wound Care.* 2003;12(1):22–28.
5. Ayurvedic Wound-Healing References
6. Prasad S, Kashyap RS, Deopujari JY, et al. Effect of topical application of Jatyadi Taila on wound healing in experimental animals. *Indian J Exp Biol.* 2019;57(5):356–362.
7. Nema NK, Maity N, Sarkar BK, Mukherjee PK. Wound healing activity of Triphala formulation on infected full-thickness dermal wound. *Phytother Res.* 2007;21(12):1153–1159.
8. Sharma R, Dash B. *Charaka Samhita.* Varanasi: Chaukhambha Orientalia; Sutrasthana, Vrana Chikitsa Adhyaya.
9. Sushruta. *Sushruta Samhita, Chikitsa Sthana, Vrana Chikitsa Adhyaya.* Varanasi: Chaukhambha Surbharati Prakashan.
10. Patil S, Deshpande A. Clinical evaluation of Jatyadi Taila in the management of Dushta Vrana. *AYU.* 2014;35(3):270–275.
11. Tripathi B. *Ashtanga Hridaya of Vagbhata.* Varanasi: Chaukhambha Sanskrit Pratishthan; Sutrasthana.
12. Peterson CT, Denniston K, Chopra D. Therapeutic Uses of Triphala in Ayurvedic Medicine. *J Altern Complement Med.* 2017;23(8):607–614.
13. Shailajan S, Menon S, Pednekar S, Singh A. Wound healing efficacy of Jatyadi Taila: in vivo evaluation in rat using excision wound model. *J Ethnopharmacol.* 2011;138(1):99–104.
14. Efficacy of Jatyadi, Madhughrita and Honey Tulle in Wound Management: A Three-arm Randomized Controlled Clinical Trial. *Journal of Ayurveda and Integrative Medicine.* 2023.
15. Dudhamal TS, Gupta SK, Bhuyan C. Role of honey (Madhu) in the management of wounds (Dushta Vrana). *Int J Ayurveda Res.* 2010;1(4):271-273. DOI:10.4103/0974-7788.76793.
16. Sharma U, Bala M, Kumar N, Singh B, Munshi RK, Bhalerao S. *Tinospora cordifolia* (Willd.) Miers ex Hook. F. & Thoms. (Guduchi): Validation of the Ayurvedic pharmacology through experimental and clinical studies. *Int J Ayurveda Res.* 2010;1(2):112-121.
17. Pachamalai R. A Case Study on Dushta Vrana with Special Reference to Venous Ulcer. *Journal of Ayurveda and Integrated Medical Sciences.* 2024
18. Shetty P, Kedukodi P, Kamath S, Udupi V. Gandhaka Rasayana: Possible Role as a Modulator of Fibroblast Cell Function in Wound Healing. *Int J Health Sci Res.* 2020;10(6):36-45.
19. Bajaj S. A review article on Dushta Vrana and its management in Ayurveda. *Ayurlog.* 2020;8(4).