

# Using of omentum pedicels for supporting ruptured urinary bladder wall in dogs

LM Alkattan

Department of Surgery and Theriogenology, College of Veterinary Medicine University of Mosul, Mosul, Iraq

**Abstract:** Cystorrhaphy with supporting omentum was performed to repair the irregular defect of urinary bladder of six dogs of both sexes. Traditional cystorrhaphy is done immediately via routine approach with single raw of suturing material then omentum harvested manually to reinforce the repaired defect. Animals were inspected clinically explored laparoscopically and grossly, X ray examination and histopathological changes were done to support the results at 15 and 30 days post surgery. Clinically the obtained results showed no abnormal changes in animals activity or behavior except mild pain and hematuria continue for two days and these signs gradually subsided. Laparoscopically and grossly shown distended urinary bladder there was no anatomical distortion or any ischemic zone at the site of operation, no any leakage of urine, the omentum adherent firmly to the site of operation 15 and 30 days post operatively. Radiographic examination showed distended urinary bladder with normal shape. Histologically 15 post surgery revealed the presence of newly granulation tissue at the line of junction with proliferation of fibroblast, at 30 days post surgery exhibited partial resorption of omentum tissue there was organized fibrotic omentum and area of well formed tensil granulation tissue. We concluded, that cystorrhaphy reinforced with omental pedicle was a feasible and mini invasive surgical technique to repair an experimental urinary bladder defect, there were no adverse side effect and massive adhesion associated with this method.

**Index Terms:** Urinary Bladder defect, Cystorrhaphy, omentum, Dogs.

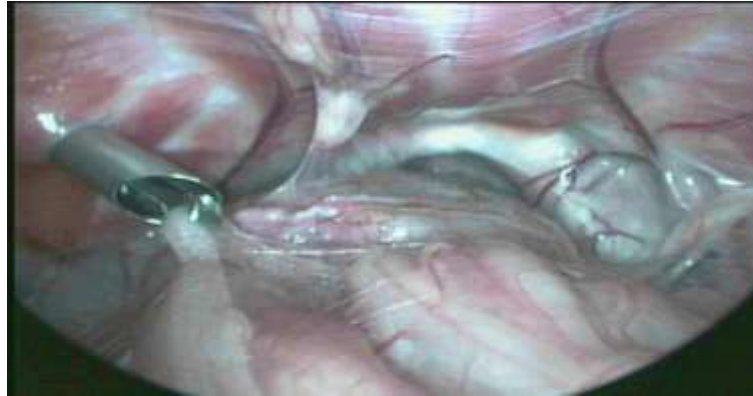## Introduction

Bladder rupture is a condition in which the urinary bladder tears and releases urine into the abdominal cavity[1]. Rupture may occur due to trauma, urinary obstruction, tumors, severe bladder disease, and during catheterization[2]. Or due to introducing trocar and during laparoscopy [3] or penetrating wounds by fractured bone or car accident [4]. This defect and subsequent uoperitoneum is a common problem in ruminants which has been associated with parturition[5]. In dogs cystorrhaphy was performed to reconstruct the defect or rupture[6]. Many Attempts to repair the defective bladder (trauma, iatrogenic injuries and infection)theses may lead to painful bladder damage or loss, so eventual bladder augmentation or substitution should be required by using gastrointestinal segments which are commonly used as tissues for bladder replacement or repair, but have been associated with multiple complications such as infection, metabolic disturbances, increased mucus production, and malignancy, several bladder substitutes have been attempted with both organic materials as peritoneum or fascia and in the past synthetics non-biodegradable materials such as poly vinyl, sponge, silicone[7]- [8].It has been used in the past but has proved to be unsuccessful because of host foreign-body reactions[9]. Different types of biodegradable material have been investigated since. In theory, biodegradable grafts would be advantageous over no biodegradable materials in that they would allow the host bladder time for regeneration but would then dissolve prior to the onset of any deleterious foreign-body reaction[10]. These materials have been applied experimentally and have shown a marked improvement over nonbiodegradable materials[10].Recent studies exhibited that using of omentum is beneficial for many purposes in veterinary practice itis used for enhancing bone healing in dogs [11]. Omentum prevents intraperitoneal infections by moving to the revealed that the omentum, apart from being a great concerned site and sealing it from the nearby source of various growth factors, neurotransmitters[12]. One of the most common applications of the omentum in veterinary medicine is placement of the omentum over sutured surgical sites in hollow organs such as the intestine or bladder, the omentum adheres to the incision site, which benefits from the omentum's pro-healing effects. Furthermore, omental adhesions prevent leakage of luminal contents through small gaps in the incision[13].

## Materials and Methods

Sex dogs of local breed underwent accident rupture via laparoscopic tool during some laparoscopic surgical interventions of urinary bladder, urine leakage into the abdomen Figure 1. The experiment was approved by Collage of Vet med University of Mosul. Aprotocol of xylazine (Xyla-Ject 2%®, Adwia - Egypt 3mg/kg.b.wt.) ketamine 10% Dutch Farm-Holand 10 mg \ kg.b.wt) were used to provide excellent analgesia and anesthesia during operation. Urgenttraditional cystorrhaphy was done by single raw suturing with Vicryl 3\0 suture material. Omentum was

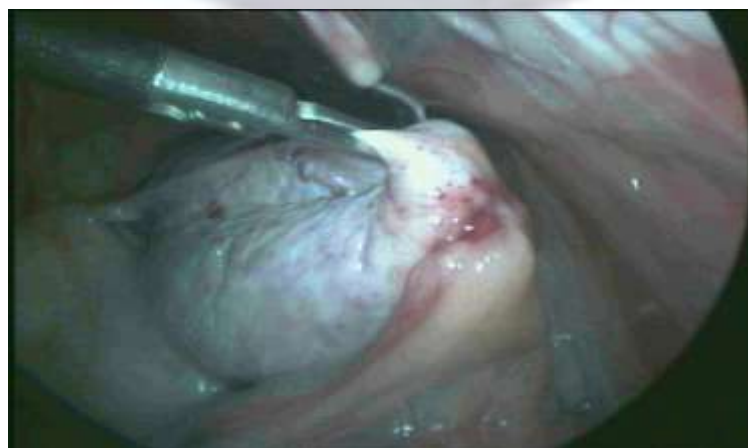
harvested from abdominal cavity then making it accessible by pulling away the adipose tissue and the omentum was localized and fixed directly upon the site of operation for wrapping it. Abdomen was closed routinely. All cases underwent a throughout daily clinical inspection, routine laparoscopic revision of the organs, gross pathological, radiological with positive contrast media (Megalamine lothalamate injection W/V60 % MAY and BAKER Ltd) and histopathological examination 15 and 30 days postoperatively.



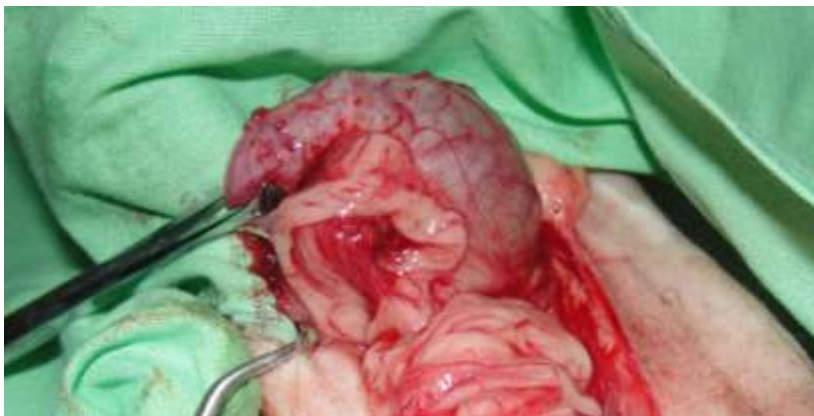**Figure 1: Showed urinary bladder penetrated with laparoscopic trocar**

### **Results**

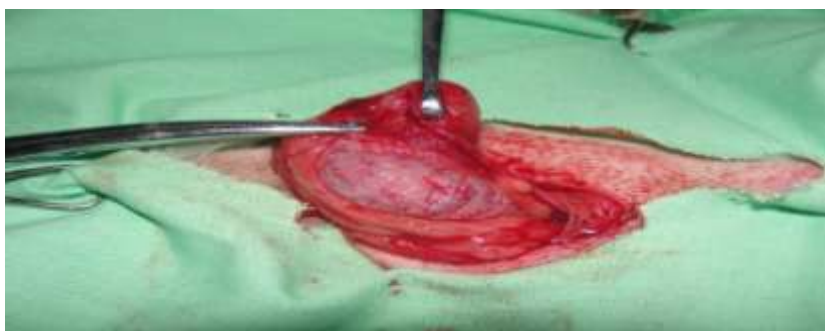Protocol of xylazine \ketamine was sufficient to produce general anesthesia for cystorrhaphy in dogs. All animals recover from anesthesia without apnea or signs of anuria. Clinically, no abnormal changes in animal activity or behavior except mild pain. Clinically the signs of pain, hematuria, urine retention or stanguriawere not detected postoperatively, only one of the treated animal underwent sever pain, this dog was treated with course of antibiotic, the sign of pain subsided gradually. Operative dogs had good appetite with no distortions in health condition during physical examination postoperatively. Exploratory laparoscopic examination 15 and 30 days postoperatively showed distended regular shape of urinary bladder, no abnormal lesion obvious on the wall of urinary bladder at site of operation, the urinary bladder wrapped with omentum, no signs of leakage Figure 2. Grossly, the omentum adherent at the site of operation no ischemic zone near the operative site 15 and 30 days post operation ( Figure 3 and 4). Radiographical examination with positive contrast media at day of operation showed irregular shape of urinary bladder wall regular distended urinary bladder, ( the perforating site) post operation (Figure 5), leakage not obvious the wall of urinary bladder seems strength, the single layer suture technique provided perfect tension with no leakage of contrast media, the bladder feature was regular with normal border, the perforating site in the wall of bladder subsided 30 days post operatively ( Figure 6). Histologically 15 post surgery revealed presence of newly granulation tissue with immature collagen baddle at the line of junction with proliferation of fibroblast, fibibrinoid exudate, congestion and mild inflammatory infilteration (Figure 7) newly granulation tissue lies between urinary bladder muscularis and omentum (Figure 8) mild adipocytolysis (Figure 9), at 30 days post surgery exhibited partial resorption of omentum tissue there was organized fibrotic omentum and an area of well formed tensil granulation tissue (Figure 10).



**Figure 2: Showed urinary bladder, the site of operation covered with omentum 30 days postoperatively**



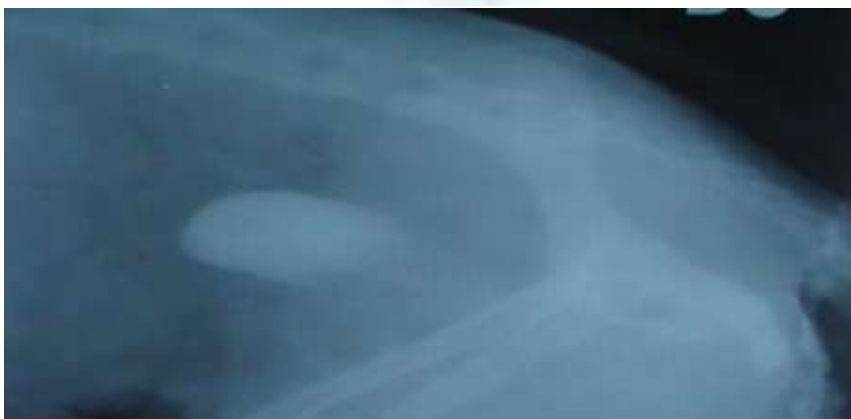**Figure, 3: Grossly urinary bladder, the site of operation covered with omentum 15 days postoperatively**



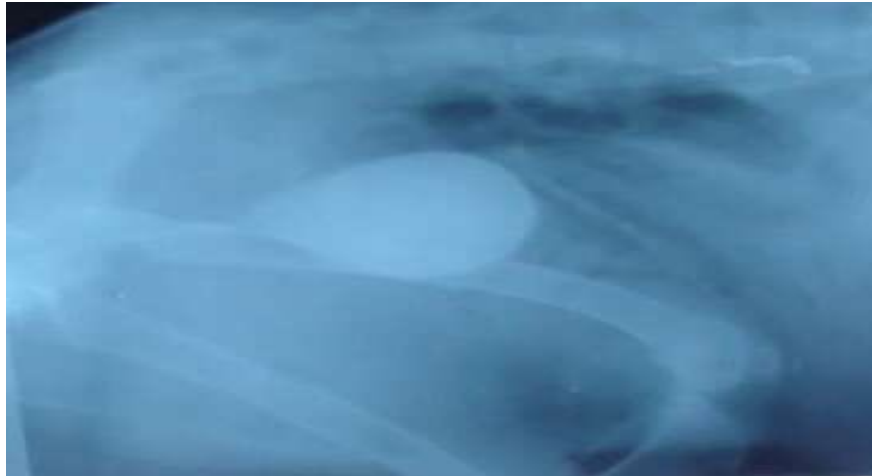
**Figure, 4: Grossly urinary bladder, the site of operation covered with omentum 30 days postoperatively**



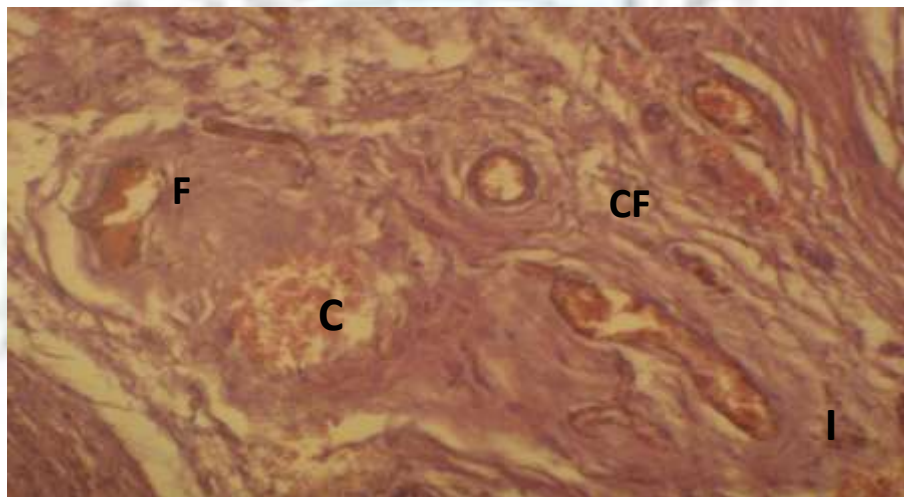
**Figure, 5: Radiographic image on lateral view at the day of operation showed the perforation site at the wall of urinary bladder .**



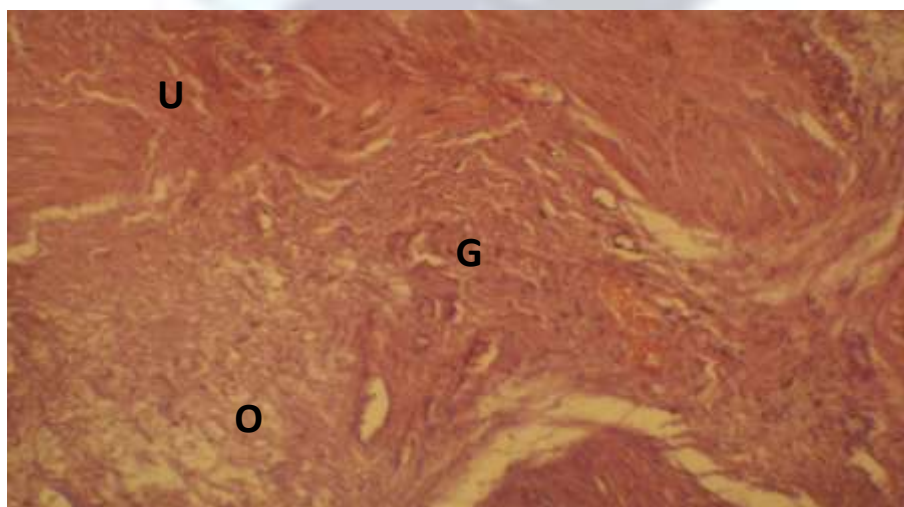
**Figure, 5: Radiographic image on lateral view at 15 days postoperatively of operation showed distended urinary bladder the perforation not obvious on the wall**



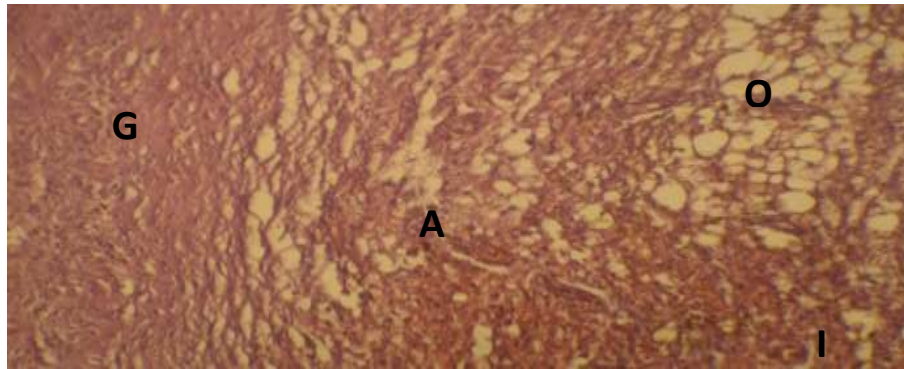
**Figure 6. Radiographic image on lateral view at 30 days postoperatively of operation showed distended urinary bladder the perforation not obvious on the wall**



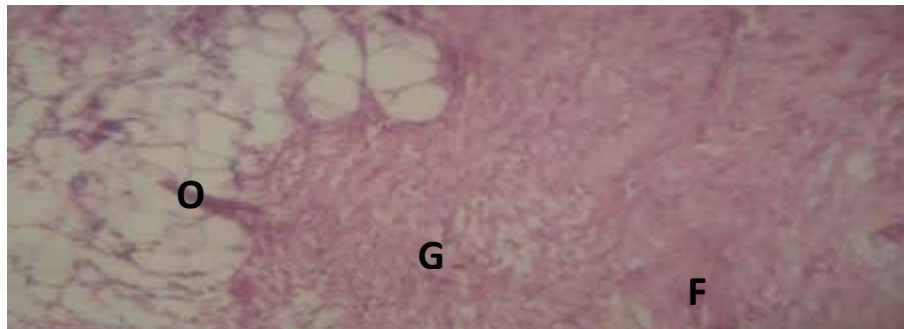
**Figure 7 : Photomicrograf of canine bladder grafted with omentum 15 days post surgery showing Congestion ( C), fibrinoid exudate ( F) Imature collagen fiber and mild inflammatory infiltration(I)200 X , H&E.**



**Figure 8 : Photomicrograf of canine bladder grafted with omentum 15 days post surgery showing urinary bladder muscularis ( U) newly granulation tissue( G) omentum(O)90 X , H&E**



**Figure 9: Photomicrograph of canine bladder grafted with omentum (O) 15 days post surgery showing newly granulation tissue (G), adipocytolysis (A) and inflammatory infiltration (I) 100 X, H&E**



**Figure 10: Photomicrograph of canine bladder grafted with omentum (O) 30 days post surgery showing well formed tensile granulation tissue (G) organized fibrotic omentum 145X, H&E**

### Discussion

Urinary bladder injury or rupture concerns as a challenge in veterinary fields, because leakage of urine into abdominal cavity irritates and is deadly if it continues for long time in the abdominal cavity. Rupture of urinary bladder occurs via many ways as imperfectly introducing trocar during laparoscopy [3]. The location of urinary bladder and the vulnerable nature of its wall acts as a predisposing factor to penetrating injury, it is considered as half of all complications via laparoscopic insertion of trocar [14]. In a present study the obtained results exhibited that the single-layer suture pattern was safe and secure for perfect closure of the perforating wound of the urinary bladder, the using of positive contrast media-tight indicates these results this consider with [15, 6]. Omentum is a vascularized tissue which has several functions as immune function, the omentum helps to control infection and wound healing of the peritoneal cavity. In a present study omentum helped in preventing infection during perforating bladder injuries. This may be due to the role of milky spots in phagocytosis, so perfect healing of penetrated wound occurs within short time [16]. The omentum plays an essential role to guard against the postoperative massive adhesion at the repairing site. This result agrees with [17], who said that the using of omentum at the anastomotic sites is essential against the postoperative per anastomotic adhesive disorders of the gut. In a present study the repaired bladder healed perfectly without any ischemic zone or any abnormal lesion or anatomical distortion. This may be due to the containing of omentum tissue, it is formed from adipose tissue with capillary network diffused at the surface of the epiploon brings a vascular support to, the intra-peritoneal organs and keep it in normal shape [17]. There was no severe adhesion between bladder and neighboring viscera this agrees with [17] this is due to the role of omentum in fibrinolytic inhibition. Adhesion of the omentum over a wound allows early revascularization, it was isolated wound from contaminants [17]. Another worker pointed that the fixation of omentum to urinary bladder is an efficient technique for the treatment of neurogenic dysfunctions of the urinary bladder. In this technique, the greater omentum helps in the reinnervation and revascularization of the bladder, this result agrees with [17].

Another worker reported that omental patch accelerated peptic ulcer healing and inhibited ulcer recurrence due to the presence of growth factor beta-1 [18]. The omentopexy promotes the local cicatrization and decreasing the risk of peritonitis, because the omentum, promoting neovascularization, granulation tissue, helping lymphatic drain [19]. The positive contrast cystography was more efficient in detecting mucosal surface irregularity, bladder displacement and intraluminal structures [20]. In this study the closure of bladder was secure so the radiographic image showed no leakage, the bladder distended the results agree with [21]. He said that the using of extracorporeal suturing with polygalactin more safe and secure for closure of an experimental cystectomy in dog, the suturing in single layer sutures has advantages that is a simple non perforating pattern. This agrees with [22, 23].

The rapid adherence of omentum to the defective area as inflamed area or peritoneal injuries may due to the role of omentum milky spots in dogs [24]. Histologically at 15 days post surgery the inflammatory cells and the newly formed blood vessel due to progressing of healing process but the inflammatory reaction had largely subsided at 30 days [25]. Angiogenesis is essential for supporting life of organism with oxygen, remove Carbon dioxide and other waste products, drain excess fluid and provide a vascular pathway for cell, mild adipocytolysis appeared, the omentum tissue is rich in fatty cells [25].

### Conclusion

In conclusion that repairing a perforating wound of urinary bladder by cystorrhaphy reinforced omentum was a feasible and very effective for preventing leakage, with no adverse side effect and adhesion associated with this method.

### Acknowledgement

Author gratefulful to Dr. Karam Hashim Almalah for his excellent support in concern to histopathological examination.

### References

- [1]. D.David. "Rupture of the Bladder in Dogs". Petplace.com. 2000.
- [2]. R.B. Jamie. "Managing traumatic urinary tract injuries in small animals". ACVS Symposium equine and small animals proceeding. pp.125-122. 2001.
- [3]. H.Goor. "Consequences and complications of peritoneal adhesions. Colorectal Disease".9(2)pp.25-34. 2007.
- [4]. [4].J.D.Summerston,D.N. Kitrey, N.Lumen, E.Serafetinidis, N.Djakovic. "Guidelines on iatrogenic trauma". European Association of urology.Pp. 62: 628.2012.
- [5]. A.J. Roussel and D.S. "Ward Ruptured urinary bladder in a heifer". J Am Vet Med Assoc.186.pp. 1310-1311. 1985
- [6]. S.T. Elzomor, E.M Sheta, O.M.El Tookhy, K.A. Ahmed, and N.A. Abd Elkader. "An experimental study of autograft for repairing urinary bladder defect in dogs" 5th Sci. Congr. of Egypt. Soc. For Anim. Manag. 18-22. Pp. 168-185. 2012.
- [7]. A.Atala. "Tissue engineering for the replacement of organ function in the genitourinary system". Am J Transplant. 4 .pp. 58-73.2004.
- [8]. Y.M Xu, Y.Qiao, Y.L Sa. "An experimental study colonic mucosal graft for urethra reconstruction". Chin Med J. 115: pp. 1163-1165. 2002.
- [9]. L. Ashkar and E.Heller. "The silastic bladder patch". J Urol. 98:pp.679-683.1967.
- [10]. H.Kambic, R.Kay, J.F Chen., M.Matsushita, H.Harasaki, S. Zilber. "Biodegradable pericardial implants for bladder augmentation: a 2.5-year study in dogs". J Urol .148: pp.539-543. 1992.
- [11]. L.M Alkattan and A.M. Alkassab. "A comparative radiological study of experimental bone and soft tissue defect healing treated with great omentum in dogs". Iraqi J of Vet Science .23(1): pp. 175-179. 2009.
- [12]. M.Alagumuth, B.B.Das, S.P. Pattanayak, and M.Rasananda. "The omentum a unique organ of exceptional versatility". Indian J Surg. 68(3): pp. 136-141. 2006.
- [13]. S. Shakeri, P.Masoudi, M.Yazdani, A.Monabbati, I. Mehraban ,D.N. Tanideh. "Evaluation of human amniotic membrane as a substitute for transitional epithelium of bladder in dog". J. Appl. Anim. Res. 33: pp.55-59. 2008.
- [14]. G.A. Vilos, J.Haeb, T.L.Crumley, M.A. Maruncic,J.H.King, J.D. Denstedt. "Serum biochemical changes after laparoscopy may be indicators of bladder injury". J Am Assoc Gynecol Laparosc. 8(2):pp.285-290. 2001.
- [15]. B.T. Abass,D.M Muhammad and A.H. Hassan. "Cystotomy Closure Using a Single-Layer Simple Continuous Versus Continuous Cushing Suture Patterns in Dogs". Al-Anbar J. Vet. Sci. 4(2). Pp.38-42.2011.
- [16]. G.Dupré. "Soft tissue surgery." SvHKS's Årsmøde, pp.11-14.2009.
- [17]. A.T.Ayman,H.W.Hisham, S. M.Samy and F H. El-Ebiary. "The protective role of pedicle of omental graft on unsafe small intestinal anastomosis an experimental study with histological evaluation in dogs"Egyptian Journal of Surgery, 22 (4):pp:534-553.2003.
- [18]. I. Gamal, M.D Moussa,H. Abdel Wahab, M.D. Gad, H Osama.M.D.El Khadrawy,M.Mahmoud M.D. Abdulrazeck, and A.Fersan and M.D.Sallam. "Omental plug technique in the treatment of large perforated peptic ulcer". Egyptian Journal of Surgery. 20 (3): pp.638-643.2001.
- [19]. F.J. Thornton, A.Barbul" Cicatrization of gastrointestinal tract "Rio de Janeiro: Interlivros. pp.547-570. 1997.
- [20]. .Gallati and I.Masao. "Comparison of ultrasonography and positive contrast cystography for detection of urinary bladder disorders in dogs". Braz J. Vet. Res. Anim. Sci. .41(1) : pp. 40-46. 2004.
- [21]. H.Waseem" Study of different methods for urinary bladder closure by assisted laparoscopy" Msc Thesis. Collage Faculty of Veterinary Medicine, Mosul University, Mosul, Iraq.2006.
- [22]. J.M.Ewoldt., D.E Anderson., M.D.Miesner and W.J. Saville" Short and long-term outcome and factors predicting survival after surgical tube cystostomy for treatment of obstructive urolithiasis in small ruminants eterinary Surgery" 35, pp. 417-422.2006.
- [23]. M.Sadeik and L.M. Alkattan"Radiological study on reconstruction of experimentaly ruptured urinarybladder tissue by using titanium cips and great omentum in dogs" Assuit vet medical J. 39(138). 2013.
- [24]. D. M. González, C. A.Hernández, J. M. Estrada. "Protective compromise of great omentum in an asymptomatic uterine rupture in a bitch": a case report Rev Colomb Cienc Pecu. 23: pp.369-376.2010.
- [25]. V.Kumar, A. KAbbas, N.Fausto and RMitchell. "Robbins Basic Pathology" 8th ed. Saunders, Elsevier.2007.