

Evaluation of Mandibular Symphysis Area among Iraqi Adolescent

Zeynab A. Ghalib¹, Dr. Neam F. Agha²

¹Dentist in Specialized Dental Center in Kirkuk, Iraq

²Assist. Prof. Orthodontic department, College of Dentistry, Mosul University, Iraq

ABSTRACT

Aims: Establishment the normative values of the mandibular symphysis of Iraqi adolescences in Kirkuk city.

Materials & Methods: 500 child, clinically examined those included subjects from Kirkuk specialized dental center, all of them were Iraqi people of Kirkuk origin, 150 radiographically examined subjects, only 125 subjects (60 females and 65 males) who fulfilled the inclusion criteria. The sample were divided in to three groups according to age (13-14, 14-15 and 15-16) years, each group subdivided in two sub groups male and female. Lateral cephalometric radiograph was taken then analyzed by Software dimaxis program, area of symphysis calculated by this program.

Results & Discussion: Generally larger mean value seen for male than for female group, this considered normal because of the aging, that an increase in bone area as increasing of age in adolescent, a significant differences found between males & females that is larger mean values seen for males at 13-14, & 15-16 years groups than females, while non significant differences found between males & females for 14-15 years group as they have the same mean value.

INTRODUCTION

The mandible come from Latin mandibula, "jawbone" or inferior maxillary bone forms the lower jaw and holds the lower teeth in place. In the midline on the anterior surface of the mandible is a faint ridge, an indication of the mandibular symphysis, where the bone is formed by the fusion of right and left processes during mandibular development. Like other symphysis in the body, this is a midline articulation where the bones are joined by fibrocartilage, but this articulation fuses together in early childhood. (Fehrenbach et al., 2012, Nita et al., 2012).

Structure:

The mandible consists of a curved, horizontal portion which is the body or base; two perpendicular parts, the ramus one on each side unite with the ends of the body at the right angles. The angle formed at this junction is called gonial angle; Alveolar process, the tooth bearing area of the mandible present above the base of the mandible; Condyle present as a projection superior and posterior from the ramus and makes the tempromandibular joint with the temporal bone; coronoid process is superior and anterior projection from the ramus (Pricop et al .,2012).

Mandibular symphysis:

It is an anatomical structure of the mandible in which the lower incisors are found including the anterior portion of the chin. Mandibular symphysis contributes to the composition and balance of facial harmony and must be considered when deciding on orthodontic treatment in borderline cases.(Arnett et al ,1999;Batista et al ,2007;Scavone et al, 2008).

Mandibular symphysis is morphologically divided into two regions, the dentoalveolar and basal symphyses:

1. The dentoalveolar symphysis includes the alveolar process and lower incisors. The long axis of the lower incisors cephalometrically matches the long axis of the alveolar process and its inclination is influenced by facial type (Martins,1991; Nojima,1998).

2. The basal symphysis is part of the main body of the mandibular symphysis with more apical location, setting the hard menton outline. The menton is considered to be a recent phylogenetic acquisition (just over 10,000 years ago), exclusive to Homo sapiens. The morphological variation of the menton has a strong genetic basis and its occurrence may have emerged casually and, did not add any biomechanical advantages for mastication (Ichimet al,2006).

Aims:

To investigate whether the age have any influence on the dimensions of mandibular symphysis. To find out whether or not there is association between the dimensions of mandibular symphysis in adolescences males and females.

MATERIALS & METHODS

The Sample:

The sample of this study involve 500 child, clinically examined those included subjects from Kirkuk specialized dental center, all of them were Iraqi people of Kirkuk origin, 150 radiographically examined subjects, only 125 subjects (60 females and 65 males) who fulfilled the inclusion criteria. 25 radiographs were excluded due to problem in cephalometric production.

Sample groups

The sample were divided in to three groups according to age (13-14, 14-15 and 15-16) years, each group subdivided in two sub groups male and female.

Criteria for Sample Specification

The following criteria were used in the selection of the sample:

1. Age range (13-16years).
2. Full permanent dentition regardless the second and third molars.
3. Good alignment of the maxillary and the mandibular teeth with less than 3mm of spacing or crowding in either arch.
4. Bilateral Class I buccal segments "molar and canine"
5. Normal over jet and overbite (2-4 mm).

The Equipment:

A. Diagnostic instruments:-

1. Disposble dental mirror and probe.
2. kidney dish.

B. Digitizing equipment:-

1. Digital Cephalometric machine, figure (1).
2. Analyzing Equipment:
 - Portable computer.
 - Analyzing software (Planmeca Dimaxis program).

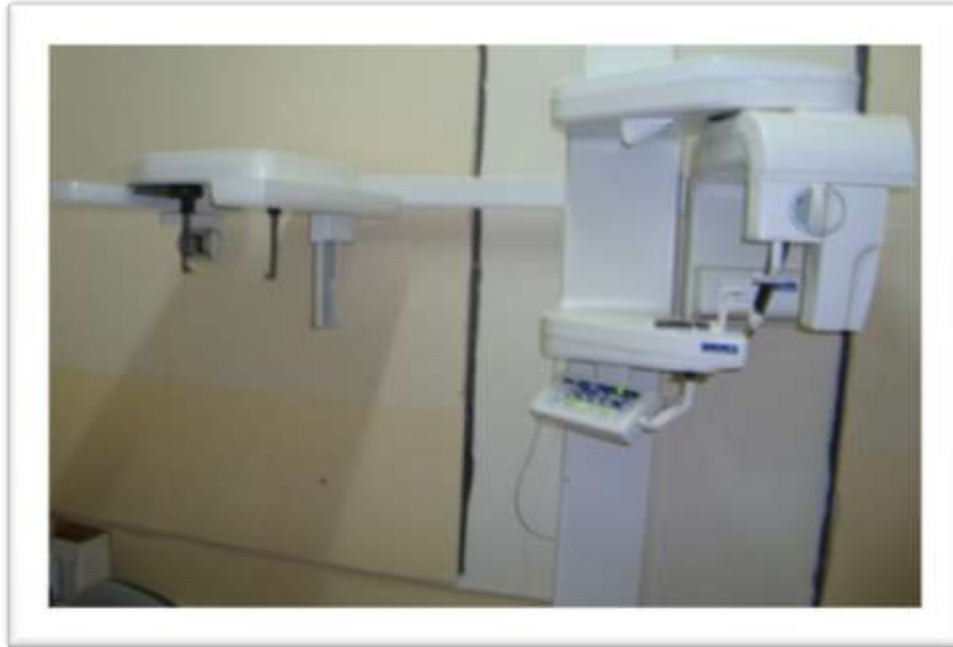

Figure (1): Digital Cephalometric Machine

Lateral Cephalometric Exposure

For the cephalometric profile recordings, the subject was asked to assume a natural head position while looking straight into his eyes in the mirror. Each subject was then instructed to keep their teeth lightly closed together (Solow et al.,1971). We put a piece of stainless steel wire 10mm for correction of magnification. Every lateral cephalometric radiograph was analyzed by Software planmeca dimaxis program to calculate the linear and angular measurements.

Landmarks:

The following landmarks were used in this study

1. Point B (Supramentale): The deepest midline point on the mandible between infradentale and pogonion. (Downs , 1948)
2. Point PM (Suprapogonion): the point at which the shape of symphismentalis changes from convex to concave, also known a protuberance menti. (Mangla et al .,2013).
3. PointPog (Pogonion): The most anterior point of the bony chin in the median plane. (Mangla et al .,2013).
4. **Pog'' (lingual pogonion):**, represents the most posterior point located in the external lingual cortical of the mandibular symphysis. (Nojima et al1998).
5. Point Go (Gonion): A point on the curvature of the angle of the mandible located by bisecting the angle formed by the lines tangent to the posterior ramus and inferior border of the mandible (Caufield, 1995).
6. Point Me (Menton): The lowest point on the symphy seal shadow of the mandible seen on a lateral cephalogram (Caufield, 1995).

METHODS

Clinical Examination

Each individual was seated on a dental chair and asked information about name, age, origin, history of facial trauma and previous orthodontic treatment. Every lateral cephalometric radiograph was analyzed by Software planmeca dimaxis program to calculate the linear and angular measurements.

The symphysis area calculated as follows:

GoMe: Mandibular plane (Tweeds) : tangent to the lower border of the mandible,

Two vertical lines to the mandibular plane were drawn one through point Band second line through SL point which represents point on the external lingual curvature of the symphysis. The intersection of these lines with the mandibular plane were marked as B' and SL'. Another line drawn from B point parallel to the mandibular plane, so the constructed lines form a parallelogram enclosing the symphysis region. The distances between these points were measured parallelism base measured as a distance from (B, to B'). While symphysis height measured as a distance from point (B) perpendicular to (S-S') line, figure (2). Total symphysial area obtained by multiplying base and height (Mess, 2012).

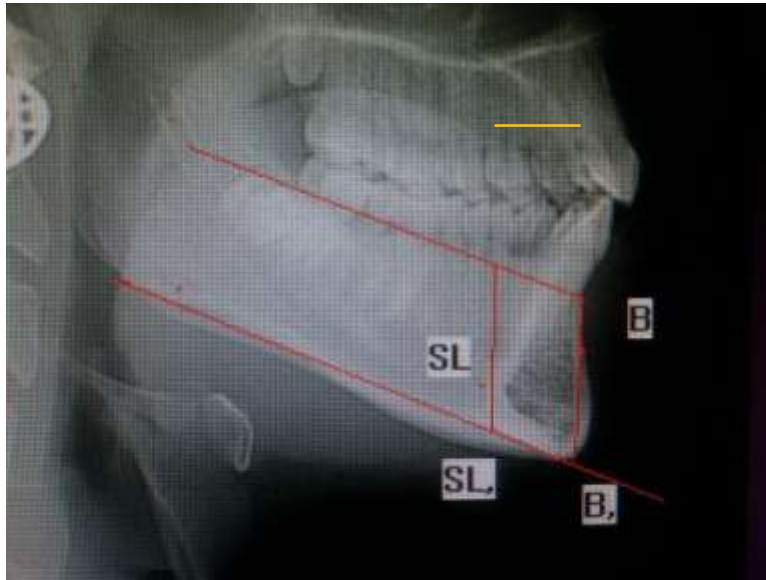


Figure (2): area of symphysis

RESULTS & DISCUSSION

In Table (1) for description of male groups, the larger mean value seen at 15-16 years group, this considered normal because of the aging, that an increase in bone area as increasing of age in adolescent.

Table (1): Descriptive Statistics for male groups

symph. Ar.	No	Minimum	Maximum	Mean	Std. Deviation
13-14y	20	199.25	278.89	244.20	20.85
14-15y	23	251.02	322.92	286.27	21.27
15-16y	22	314.29	340.85	324.32	17.19
total	65	199.25	340.85	262.76	20.56

The least symphysial area, in minimum & maximum & mean values, seen is 13-14 years group. The same reason of aging for adolescent.

In table (2) for description of female groups, the larger mean value seen at 15-16 years group, this is the same as male group, that an increase in bone area as increasing of age in adolescent.

Table (2): Descriptive Statistics for female groups

symph. Ar.	No	Minimum	Maximum	Mean	Std. Deviation
13-14y	21	186.66	279.07	229.46	27.16
14-15y	21	240.16	319.55	286.46	24.62
15-16y	18	265.76	307.25	284.66	23.85
total	60	186.66	319.55	259.97	21.80

The least symphyseal area, in minimum & maximum & mean values, seen is 13-14 years group. Also, the same as male group, which due to aging of adolescent.

In table (3), for comparison between males & females in three age groups. We found, a significant differences found between males & females that is larger mean values seen for males at 13-14, & 15-16 years groups than females. Non significant differences between the two genders at 14-15 years group, as they have the same mean values.

Table (3): comparison between males & females in three age groups

age	gender	Mean	SD.	t	Sig.
13-14y	M	244.20	20.85	2.183	.042
	F	229.46	27.16		
	T	236.68	25.13		
14-15y	M	286.27	21.27	0.041-	.968
	F	286.46	24.62		
	T	286.36	22.67		
15-16y	M	324.32	17.19	7.517	.000
	F	284.66	23.58		
	T	364.47	47.48		

Almost all mandibular anterior bone measurements were greater in the male subjects than in the female subjects. (Uysal et al, 2012). This may have been caused by age difference between males and females. However, there is a chronological gap between growth and development of males and females in the phase of adolescence, including the vertical development of the face. Additionally, females in general have their pubertal growth spurt at an earlier age than males. Therefore, growth will likely be more balanced between males and females in this condition, with a mean age difference of 1.56 years during adolescence, particularly because females represented the group with the lower average age. Similar findings were also reported in other studies. (Jones, 1966; Takahashi, 2002; Paiva et al, 2014).

This came in accordance with conclusions of other studies, (Locks,1981; Locks,1996). which reported that the skeletal gender variation probably due to that male grow at faster rate and over long period of time than female.

Regarding gender, the results showed a significant difference for Symph Ar. both male and female mandibular symphyses have a similar thickness for basal symphysis. (Arruda et al, 2012). values of symphyseal dimensions are essential, as it is commonly agreed that an especially narrow symphysis is an etiological factor in the development of fenestrations and dehiscences. (Artun et al, 1987; Wehrbein,1996). Although symphyseal parameters have already been studied in earlier works, the present results can only be compared to those numbers with caution, as the definition and identification of symphyseal landmarks may differ from author to author, rendering a direct comparison of absolute values questionable. In agreement with our findings, other authors also attested to a continuous increase of symphyseal height throughout the entire observed child hood (Aki et al, 1994; Bhatia, Leighton,1993;Riolo et al ,1974). an additional observation is supported by the literature: The very modest gain in symphyseal height up to point B (distance H1) (Bhatia, Leighton,1993) and the excessive vertical increase for symphyseal height up to the tip of the lower incisors (distance H2). (Aki et al,1994;Riolo et al,1974). This discovery, ie, that most of the changes occur in the dentoalveolar part of the symphysis, seems to reflect previous statements that the anterior basal part of the symphysis remains a stable landmark. (Bjork,1963; Bjork, 1969). Similarly, only little alteration can be witnessed in symphyseal width (distance W), with an increase of 1 mm for females and 2 mm for males over the entire observed period. This is in agreement with Riolo et al, 1974 but not with Aki et al, 1994 who measured a more significant increase in the sagittal dimension of the symphysis. (Gütermann et al ,2014).

REFERENCES

- [1]. Illustrated Anatomy of the Head and Neck, Fehrenbach and Herring, Elsevier, 2012,
- [2]. TiberiuNiță, Vasilios Panagopoulos, Laurențiu Munteanu, Alexandru Roman (Mar 2012). Customised osteosynthes is with mini plates in anatomico-clinical forms of mandible fractures.
- [3]. Marius Pricop, Horațiu Urechescu, Adrian Sîrbu (Mar 2012). Fracture of the mandibular coronoid process.
- [4]. Arnett GW, Jelic JS, Kim J, Cummings DR, Beress A, Worley CM Jr et al. Soft tissue cephalometric analysis: diagnosis and treatment planning of dentofacial deformity. Am J Orthod Dentofacial Orthop. 1999; 116:239-53.
- [5]. Batista KBSL, Paiva JB, Rinoneto J, Queiroz GV, Bozzini MF, Farias B. Avaliação estegumentares, esqueléticas e dentárias do perfil facial. Rev ClinOrtodon Dental Press. 2007;5:95-105.

- [6]. Scavone H, Zahn-Silva W, do Valle-Corotti KM, Nahás AC. Soft tissue profile in white Brazilian adults with normal occlusions and well-balanced faces. *Angle Orthod.* 2008;78:58-63.
- [7]. Martins AN. Inclinação da sínfise em relação aos padrões faciais em pacientes leucodermas, sul-brasileiros, portadores de má-oclusão de Classe I, de Classe II (divisão I) e de Classe III de Angle. *Ortodontia Paranaense.* 1991;12:1-19.
- [8]. Nojima K, Nakakawaji K, Sakamoto T, Isshiki Y. Relationships between mandibular symphysis morphology and lower incisor inclination in skeletal Class III malocclusion requiring orthognatic surgery. *Bull Tokyo Dent. Coll* 1998;39:175-81
- [9]. Ichim I, Swain M, Kieser JA. Mandibular biomechanics and the development of the human chin. *J Dent Res.* 2006;85:638-42
- [10]. Caufield PW. Tracing technique and identification of landmarks. In Jacobson A. *Radiographic cephalometry from basics to videoimaging.* Quintessence Publishing Co, Inc; 1995.p. 60.
- [11]. Downs WB. Variations in facial relationships: their significance in treatment and prognosis. *Am J Orthod* 1948; 34(10): 812-40.
- [12]. Rajat Mangla, Navjot Singh,¹ Vinay Dua, Prajeesh Padmanabhan,¹ and Manu Khanna. Evaluation of mandibular morphology in different facial types. *Contemp Clin Dent.* 2011 Jul-Sep; 2(3): 200–206.
- [13]. Tancan Uysal, Ahmet Yagci, Torun Ozer, Ilknur Veli, Ahmet Ozturk. Mandibular anterior bony support and incisor crowding: Is there a relationship? *American Journal of Orthodontics And Craniofacial Orthopedics.* 2012 Nov;142(5):645-653.
- [14]. Fabiano Paiva Vieira,¹ Arnaldo Pinzan,² Guilherme Janson,³ Thais Maria Freire Fernandes,⁴ Renata Carvalho Sathler,⁵ and Rafael Pinelli Henriques.⁶ Facial height in Japanese-Brazilian descendants with normal occlusion. *Dental Press J Orthod.* 2014 Sep-Oct; 19(5): 54–66.
- [15]. Jones BH, Meredith HV. Vertical change in osseous and odontic portions of human face height between the ages of 5 and 15 years. *Am J Orthod.* 1966;52(12):902-21.
- [16]. Takahashi R. Determinação cefalométrica das alturas faciais anterior e posterior, em jovens brasileiros, descendentes de xandodermas e leucodermas, com oclusão normal [tese]. Bauru (SP): Universidade de São Paulo; 2002.
- [17]. Locks A. Análise das proporções verticais anteriores da face de indivíduos brasileiros, portadores de oclusão excelente e perfil agradável [mestrado]. Rio de Janeiro (RJ): Universidade Federal do Rio de Janeiro; 1981. [Links]
- [18]. Locks A. Estudo cefalométrico das alturas faciais anterior e posterior, em crianças brasileiras, portadoras de má-oclusão Classe I de Angle, na fase de dentadura mista [tese]. Araraquara (SP): Universidade Estadual Paulista; 1996.
- [19]. Karine Evangelista Martins Arruda; José Valladares Neto; Guilhermede Araújo Almeida Assessment of the mandibular symphysis of Caucasian Brazilian adults with well-balanced faces and normal occlusion: the influence of gender and facial type. *Dental Press J. Orthod.* vol.17 no.3 Maringá May/June 2012.
- [20]. Artun J, Krogstad O. Periodontal status of mandibular incisors following excessive proclination. A study in adults with surgically treated mandibular prognathism. *Am J Orthod Dentofacial Orthop.* 1987; 91:225–232.
- [21]. Wehrbein H, Bauer W, Diedrich P. Mandibular incisors, alveolar bone, and symphysis after orthodontic treatment. A retrospective study. *Am J Orthod Dentofacial Orthop.* 1996;110:239–246.
- [22]. Aki T, Nanda RS, Currier GF, Nanda SK. Assessment of symphysis morphology as a predictor of the direction of mandibular growth. *Am J Orthod Dentofacial Orthop.* 1994;106:60–69.
- [23]. Bhatia SN, Leighton BC. *A Manual of Facial Growth.* Oxford: Oxford University Press; 1993.
- [24]. Riolo ML, Moyers RE, McNamara JA Jr, Hunter WS. *An Atlas of Craniofacial Growth.* Ann Arbor, Mich: Center for Human Growth and Development, University of Michigan; 1974.
- [25]. Bjork A. Prediction of mandibular growth rotation. *Am J Orthod.* 1969;55:585–599.
- [26]. Bjork A. Variations in the growth pattern of the human mandible: longitudinal radiographic study by the implant method. *J Dent Res.* 1963;42:400–411.
- [27]. Cécile Gütermann^a; Timo Peltomäki^b; Goran Markic^c; Michael Hänggi^a; Marc Schätzle^c; Luca Signorelli^a; Raphael Patcas^c The inclination of mandibular incisors revisited. *The Angle Orthodontist:* January 2014, Vol. 84, No. 1, pp. 109-119.