

Endodontic Management and Reinforcement of a Taurodont Tooth with Fiber Reinforced Composite: A Case Report

Dr. Abhinav Kumar Singh¹, Dr. Saurabh Garg², Dr. Deepak J. Parekh³,
Dr. Neal Bharat Kedia⁴, Dr. Achla Bharti Yadav⁵, Dr. Sumit Kumar Yadav⁶

¹Reader Dept. of Conservative Dentistry & endodontics, Buddha Institute Of dental Sciences & hospital Patna (Bihar)

²Endodontist, Private Practitioner Panipat (Haryana)

³Endodontist, Private Practitioner Hyderabad (Telangana)

⁴Associate Professor, Deptt. of Orthodontics & Dentofacial Orthopedics, Buddha Institute of Dental Sciences & Research Patna, Bihar, India

⁵Demonstrator, Department of Oral Pathology & Microbiology, Government Dental College, PGIDS, Rohtak, Haryana, India

⁶Reader, Department of Orthodontics & Dentofacial Orthopedics, Mithila Minority Dental College & Hospital, Darbhanga, Bihar, India

ABSTRACT

Taurodontism is the morphoanatomical change in the shape of a tooth, which involves enlargement of the body of the tooth and shortening of the roots. Although a rare dental anomaly, unusual radicular form presents with challenging endodontic considerations. Endodontic management of taurodont teeth has been described as complex and difficult. The present article describes a brief literature review and endodontic treatment of maxillary left molar with hypertaurodontism followed by need for post endodontic rehabilitation with fibre reinforced composite.

Keywords: Endodontic treatment, enlarged pulp chamber, first molar, taurodontism.

INTRODUCTION

The term Taurodontism comes from the Latin term tauros, which means 'bull' and the Greek term odus, which means 'tooth' or 'bull tooth' (Keith 1913, Terezhalmly et al. 2001). It was first described by Gorjanovic-Kramberger (1908); however, the term taurodontism was first introduced by Sir Arthur Keith (Keith 1913) based on studies on multi rooted teeth of Neanderthal man. It was thought that this anomaly was absent in modern man. However there are an increasing number of reports of taurodontism in present day man in permanent dentition, deciduous dentition or both concurrently (Shifman A et al 1978, Ruprecht et al 1987, MacDonald-Jankowski & Li 1993, Darwazeh et al. 1998, Terezhalmly et al. 2001, Neville et al. 2002, Bhat et al. 2004, Rao & Arathi 2006), unilaterally or bilaterally, and in any combination of teeth or quadrants (White & Pharoah 2004).

Taurodontism is a developmental disturbance of a tooth that lacks constriction at the level of the cemento-enamel junction and is characterized by vertically elongated pulp chambers, apical displacement of the pulpal floor, and bifurcation or trifurcation of the roots (Brkic & Filipovic 1991, Hargreaves & Goodis 2002, Jafarzadeh H et al 2008)

Mangion() has attributed the etiology of taurodontism as a) A specialized or retrograde character b) A primitive pattern c) A mandelian recessive trait d) An atavistic feature e) A mutation resulting from odontoblastic deficiency during dentinogenesis of the roots. However, according to some authors (Hamner et al 1964, Terezhalmly et al. 2001) it is caused by the failure of Hertwig's epithelial sheath diaphragm to invaginate at the proper horizontal level.

Taurodontism may have a genetic basis and can appear as an isolated trait or in combination with other anomalies (Jafarzadeh H et al 2008, Haskova JE 2009) namely Cleft lip and palate, Thalassaemia major, Mohr syndrome (Mednick GA, 1973), Tridentoosseous syndrome, Down's syndrome (Jasper MT 1981), Ectodermal Dysplasia, Smith – Magneis

syndrome, Pulpal calcification, Amelogenesis imperfecta and rarely with Klinefelter syndrome (Yeh and Hsu, 1998). A certain familial tendency has been reported in the presentation of taurodontism and Fischer has described a case wherein 12 members of same family had taurodont (Fisher H, 1961).

Some authors (Whitkop et al 1988, Varella and Alvesalo 1989) have established a close association of taurodontism and X-linked chromosomal aneuploidy. They concluded that the gene content of the X-chromosome, rather than the amount of heterochromatin, is the cause of taurodontism in individuals with chromosome aneuploidy (Varella J, Alvesalo L 1989).

The reported prevalence of taurodont molars and premolars ranges from 0.25- 11.3% (Haskova JE, 2009), 1% in modern man and 3% in primitives, Eskimos and American Indians (Bhat et al 2004), 2.5-3.2% of population (Neville et al 2002). Most studies have found equal distribution between males and females. Permanent mandibular molars are most commonly affected (MacDonald-Jankowski & Li 1993, Rao & Arathi 2006).

Differences of opinion exist as to how much displacement and/or morphologic change constitutes taurodontism. Most authors do not provide an objective analysis of cases presented, preferring a subjective diagnosis.

In 1928, Shaw classified teeth as cynodont, hypotaurodont, mesotaurodont and hypertaurodont, in terms of increasing degree of severity of apical displacement of the pulp chamber floor (Figure 1).

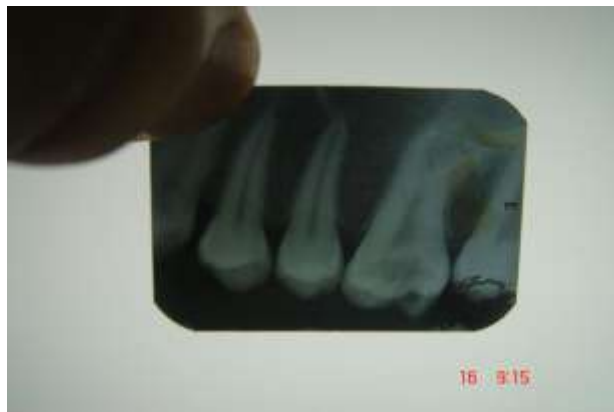

Fig. 1: Pre Operative

Hypotaurodont: moderate enlargement of the pulp chamber at the expense of the roots

Mesotaurodont: pulp is quite large and the roots short but still separate

Hypertaurodont: prismatic or cylindrical forms where the pulp chamber nearly reaches the apex and then breaks up into 2 or 4 channels

Single or pyramidal root (cuneiform): usually in the lower second molar where the pulp extends throughout the root without cervical constriction and exits via a single wide apical foramen

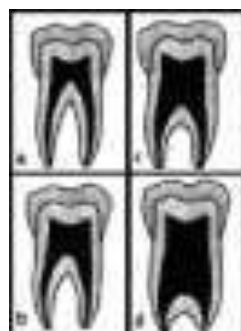


Figure 2

‘Taurodont index’ relating the height of the pulp chamber to the length of the longest root was proposed by Keene in 1966. Blumberg believed that taurodontism is a continuous trait and therefore cannot be put into strict categories (Blumberg 1971). He proposed several variables in a biometric study. Shifman and Chananel established more objective criteria on the basis of determined measurement of the tooth. A tooth is taurodont when the distance from the lowest point of pulp chamber roof to the highest point of the floor divided by the distance from the lowest point of pulp chamber roof to root apex is 0.2mm or greater and of distance from the highest point of the floor to cemento enamel junction greater than 2.5mm. Taurodontism though not common, is an important occurrence that may influence the dental management of patients. Clinical considerations related to it are, susceptibility to root resorption during orthodontic treatment, extractions are more difficult as furcation is located more apically and root apices may be shorter and thinner, anchorage value of teeth may be reduced.

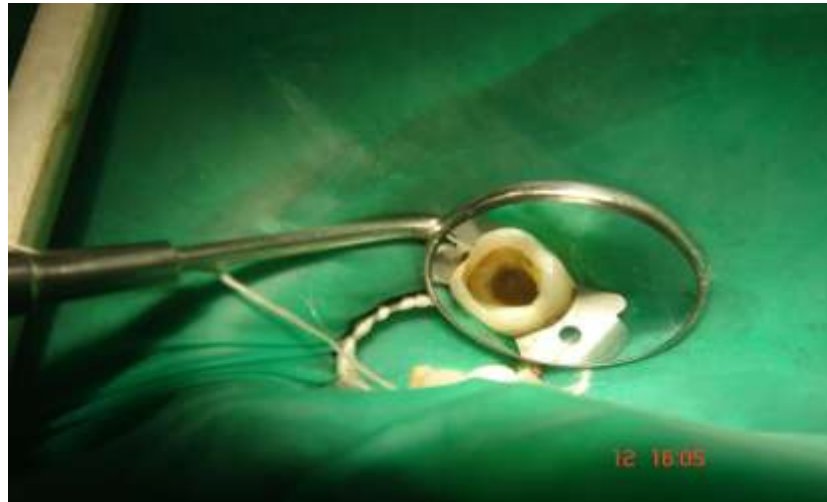

Fig. 3: clinical picture

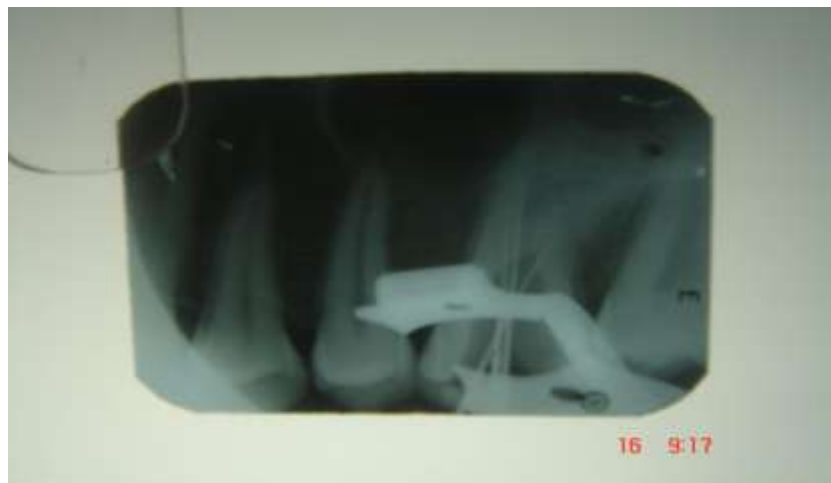

Fig. 4: working length

CASE REPORT

A 17 year old male patient reported to the Department of Conservative Dentistry and Endodontics, College of Dental Sciences, Davangere, India, with the chief complaint of recurrent pain over the maxillary left first molar for a period of 2 months. His medical and familial history revealed no systemic disorders. Clinical examination showed a deep coronal carious lesion with no evidence of tenderness on percussion, swelling and sinus tract. Vitality test with heated gutta percha

stick, and electric pulp tester (Parkell, USA) revealed severe, rapid, lingering pain from the maxillary left first molar. Pre-operative periapical radiograph revealed deep occlusal caries involving the pulp, no evidence of periapical pathology was seen. Based on clinical and radiological evidence it was diagnosed as chronic irreversible pulpitis. Radiographic examination of the affected tooth revealed an abnormal tooth anatomy. The radiographic findings were:

- The pulp chamber extended beyond the cervical area reaching the furcation.
- Three short roots were seen at the furcation area in the apical third.

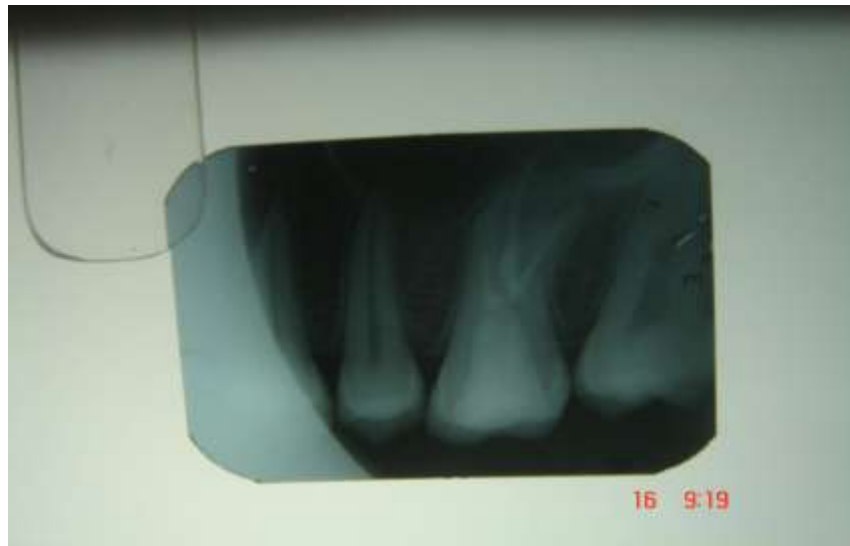

Fig. 5: post obturation

From these radiographic findings, the tooth was diagnosed to be a hypertaurodont (Shifmann and Chanannel classification). The treatment was started with administration of local anesthesia using 2% lidocaine hydrochloride with 1:200,000 adrenaline. Tooth was isolated using rubber dam and caries removed prior to access opening. The pulp was voluminous and extirpated from pulp chamber using 60 size 'H' file. To ensure complete removal, 2.5% sodium hypochlorite was initially used as an irrigant to soften the pulp. Once the pulp was extirpated, further irrigation was done with normal saline, 3% of hydrogen peroxide and 2.5% of sodium hypochlorite. The pulp chamber was huge and the floor of the chamber could not be visualized. At the furcation area, using operating microscope, three canal orifices were located: palatal, mesiobuccal and distobuccal. A working length radiograph was taken with a #15 file in the canal and it was confirmed by an electronic apex locator (Root ZX; Morita, Japan) .

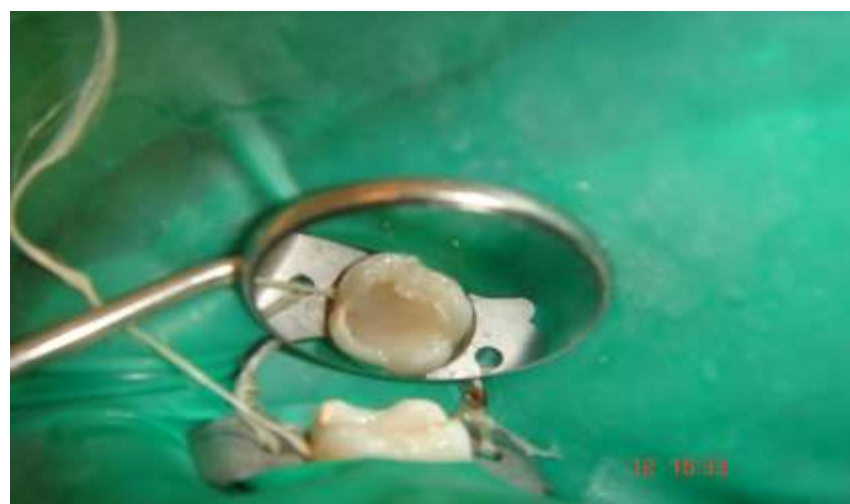

Fig. 6: reinforcing with fibre reinforced composite

The three canals were thoroughly instrumented using nickel titanium rotary technique and apical preparation to a size of 25 with 4% K3 (Sybron Endo, Orange, CA, USA) in both buccal canals and to a size 40 with 6% K3 (Sybron Endo, Orange, CA, USA) in palatal canal was done using torque control motor (EX-Smart, DENSPLY). The huge pulp chamber walls were planed circumferentially using 60 size 'K' files of standard ISO taper. Sterile saline was used as the final irrigant and ultrasonic irrigation was done. Canals were obturated with corresponding GP points (Sybron Endo, Orange, CA, USA).

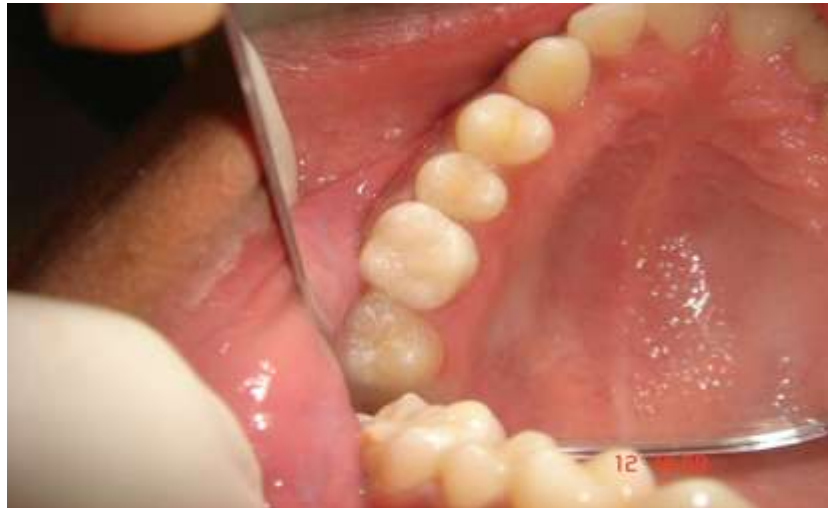

Fig. 7: final restoration

It was decided to use unidirectional Glass Fiber Reinforced Composite (Splint-IT, Pentron Clinical Technologies) to rehabilitate the tooth dentine. Smear layer removal was done with 17% EDTA solution and 5.25% sodium hypochlorite. 37% phosphoric acid (Etchant) was syringed into the pulp chamber and left for 15 seconds, rinsed off and 5th generation bonding agent was applied and cured. Flowable composite resin (Filtek Z250, 3M ESPE) was injected into the canal and a premeasured 3mm strip of glass fiber (Splint-IT, Pentron Clinical Technologies) was coated with bonding resin and placed into the canal. The fibers were compressed onto the walls of the pulp chamber and cured using Elipar LED Curing Light (3M ESPE) for 120 seconds. Fiber reinforced composite resin rehabilitation was completed upto the mid crown using incremental layered adhesion technique. Prior to complete curing dentin shade photocured hybrid composite resin () was compressed into the occlusal portion and light cured for 2 minutes. Final shaping was accomplished with diamonds and fluted carbide burs. A final radiograph to determine the quality of restoration was taken. The patient was asymptomatic and comfortable during recall after 1 month and 6 months.

DISCUSSION

Endodontic treatment in taurodont teeth has been described as complex and difficult (Prakash R et al 2005). A taurodont tooth shows wide variation in the size and shape of the pulp chamber, varying degrees of obliteration and canal configuration, apically positioned canal orifices, and the potential for additional root canal systems (Jafarzadeh H et al 2008). The floor of the pulp chamber is more apically positioned, making localization and instrumentation of the root canal orifices more difficult. The number of roots and root canals is variable, adding to the problem of endodontic management (Haskova JE 2009).

The results of pulp testing contribute little information about the effect of a large pulp chamber on tooth sensitivity (Durr et al. 1980). Moreover, when bifurcated (or trifurcated), a pronounced curve is usually present in each of the roots making gauging the apical curves an essential step in these cases.

A complicated root canal treatment has been reported for a mandibular taurodont tooth with five canals, only three of which could be instrumented to the apex (Hayashi 1994). Therefore, careful exploration of the grooves between all orifices, especially with magnification (Tsesis et al. 2003), has been recommended to reveal additional orifices and canals (Yeh & Hsu 1999).

A modified filling technique has been proposed, which consists of combined lateral compaction in the apical region along with vertical compaction of elongated pulp chamber (Tsesis et al. 2003). It is the intent of present technique to utilize the inherent tensile strength of the reinforcement fiber, the flexibility and strength of the resin/glass fiber complex and high bond strength of bonding agent. The glass fiber reinforcement material used is made from biocompatible, ultra high modulus, high molecular weight glass fibers and is coated with bonding resin and intimately adapted to the walls of the preparation.

It has been reported that the use of bonding agent together with a composite resin strengthens and reinforces endodontically treated tooth. With the use of 5th generation bonding agents, the strength of the bond to the surrounding dentin can be greater than cohesive strength of the dentin itself. It is assumed that this technique strengthens the root, reducing the probability of fracture of coronal tooth structure.

REFERENCES

- [1] Bhat SS, Sargod S, Mohammed SV (2004) Taurodontism in deciduous Molars-a Case Report. *Journal of the Indian Society of Pedodontics and Preventive Dentistry* **22**, 193-6.
- [2] Blumberg JE, Hylander WL, Goepf RA (1971) Taurodontism: a biometric study. *American Journal of Physical Anthropology* **34**, 243-55.
- [3] Brkic H, Filipovic I (1991) The meaning of taurodontism in oral surgery-case report. *Acta Stomatologica Croatica* **25**, 123-7.
- [4] Durr DP, Campos CA, Ayers CS (1980) Clinical significance of taurodontism. *Journal of the American Dental Association* **100**, 378-81.
- [5] Goaz PW, White SC (1994) *Oral Radiology (Principles and Interpretation)*, 3rd edn. Louis, USA: Mosby
- [6] Gorjanovic - Kramberger K. *Uber prismatische Molarwurzeln rezenter und diluvialer Menschen. Anat Anz* 1908;32:401-30.
- [7] Hargreaves KM, Goodis HE (2002) *Seltzer and Bender's Dental Pulp*, 3rd edn. Chicago: Quintessence Pub Co. Hata S,
- [8] Hammer JE III, Witkop CJ Jr, Metro PS Taurodontism: Report of a Case. *Oral Surgery* **18**: 409 -418 :1964
- [9] Jaspers MT (1981) Taurodontism in the Down syndrome. *Oral Surgery, Oral Medicine and Oral Pathology* **51**, 632-6.
- [10] Keith A. Problems relating to the teeth of the earlier forms of prehistoric man. *Proc R Soc Med* 1913; **6**:103-10.
- [11] Mangion, J.J.: Two cases of Taurodontism in Modern Human Jaws, *Br. Dent. J.* 309-312, 1962.
- [12] Mednick GA (1973) Two case reports: taurodontism and taurodontism in Kleinfelter's syndrome. *Journal of the Michigan Dental Association* **55**, 212-5.
- [13] Neville BW, Damm DD, Allen CM, Bouquot JE (2002) *Oral & Maxillofacial Pathology*, 5th edn. Philadelphia: W.B. Saunders.
- [14] Rao A, Arathi R (2006) Taurodontism of deciduous and permanent molars: report of two cases. *Journal of the Indian Society of Pedodontics and Preventive Dentistry* **24**, 42-4.
- [15] Ruprecht A, Batniji S, El-Neweihi E. Incidence of taurodontism in dental patients. *ORAL SURG ORAL MED ORAL PATHOL* 1987;63:743-7.
- [16] Shifman A, Chanannel I. Prevalence of taurodontism found in radiographic dental examination of 1,200 young adult Israeli patients. *Community Dent Oral Epidemiol* 1978; **6**:200-3.
- [17] Shaw JCM. Taurodont teeth in South African races. *J Anat* 1928; **62**:476-98.
- [18] Varrela J, Alvesalo L (1989) Taurodontism in females with extra X chromosomes. *Journal of Craniofacial Genetics and Developmental Biology* **9**, 129-33.
- [19] Witkop CJ Jr, Keenan KM, Cervenka J, Jaspers MT (1988) Taurodontism: an anomaly of teeth reflecting disruptive developmental homeostasis. *American Journal of Medical Genetics* **4**, 85-97.